

Clinical Article

CORRECTION OF SIALOCELE IN A GERMAN SHEPHERD DOG

Rukmani Dewangan, M.O. Kalim, S.K. Tiwari, R. Sharda and A.S. Sengar

Department of Veterinary Surgery and Radiology
College of Veterinary Science & A.H., Anjora, Durg (C.G.)

Abstract: A four years old German shepherd dog was brought to the Department of Veterinary Surgery and Radiology with complaint of swelling under the rear portion of the jaw since last 2 weeks. On clinical examination soft, non-painful swelling under the lower jaw was observed and no swelling was under the tongue or in the back of the mouth. The swelling was soft and feel like fluid within a pocket of tissue. On fine-needle aspiration, the swelling is filled with saliva which was blood tinged fluid and thick like mucoid. General anaesthesia was achieved using Atropine sulphate- 0.02 mg /kg i/m, Xylazine- 1mg/kg i/m and Ketamine- 5 mg/kg i/v and complete drainage of the sialocele was done. After flushing with normal saline, cauterization with 2% silver nitrate was done. Then suturing was done with silk using simple interrupted sutures. Post-operative care was done by using Intacef (500mg), Meloxicum (2ml) alongwith antiseptic dressing with betadine solution and sliversulfadiazine ointment for 5 days. Suture was removed after 7 days. No recurrence was reported upto 2 months of post surgery.

Keywords: Sialocele, mucocele, dog.

Introduction

A salivary mucocele or sialocele is an abnormal accumulation of saliva in the subcutaneous tissue adjacent to a damaged salivary gland or duct and is surrounded by granulation tissue. The saliva originates from a ruptured salivary gland or duct. A cervical mucocele is a collection of saliva in the deeper structures of the intermandibular space, the angle of jaw, or the upper cervical region. The sublingual and mandibular salivary glands are most commonly affected (Hedlund and Fossum, 2007). In most cases, the inciting cause of a salivary mucocele is usually unknown although blunt trauma, salivary gland or duct foreign bodies, sialoliths, and dirofilariasis have been suggested (Dunning, 2003). The sialocele has a non-epithelial non-secretory lining consisting primarily of fibroblast and capillaries (Smith 2000). Mucoceles differ from a true “cyst” in that they are lined by inflammatory connective tissue rather than an epithelial lining. The diagnosis of salivary mucocele is based on the history, clinical signs and aspiration cytology of the affected region. Affected animals are presented with soft and fluctuant swellings which are painless except in the acute phase of the

*Received April 9, 2016 * Published June 2, 2016 * www.ijset.net*

inflammatory response. The overall incidence of salivary gland diseases in dogs and cats is low, among that dogs are more frequently affected (Waldron and Smith, 1991). All breeds are susceptible, but some reports indicate that poodles, German shepherds, Dachshunds and Australian Silky terriers are more commonly affected and which predominantly occurred in small dogs (Hedlund and Fossum, 2007). Male dogs are more commonly affected (79%) than females and all age groups can develop mucocele. The sublingual salivary gland is most commonly involved (Dunning, 2003). Saliva takes the path of least resistance, most commonly accumulating in the cranial cervical or intermandibular, sublingual or pharyngeal tissue (Benjamino, *et al.*, 2012). In the present paper reports successful management of salivary mucocele in a German shepherd dog.

Case history

A four years old German shepherd dog was brought to the Department of Veterinary Surgery and Radiology with complaint of swelling under the rear portion of the jaw since last 2 weeks. On clinical examination, a very large fluctuant, non painful fluid filled mass was evident in the cervical and intermandibular region (fig.1). Body temperature, pulse, and respiration were within normal range. The dog continued to eat and drink normally until the day of presentation. Based on the history and clinical findings, cervical mucocele was suspected. On needle aspiration of the mass under aseptic conditions a thick mucoid, blood tinged fluid confirmed the presence of saliva and a diagnosis of sialocele.

Surgical procedure

After aseptic preparation of the animal, general anaesthesia was achieved using Atropine sulphate- 0.02 mg /kg i/m, Xylazine- 1mg/kg i/m and Ketamine- 5 mg/kg i/v. The affected side was determined to be the left side by placing the animal in dorsal recumbency. On fine-needle aspiration at the dependent areas of the sialocele, the swelling is filled with saliva which is thick like mucoid and blood tinged fluid. Through a stab incision in the most ventrally dependant area complete drainage of the sialocele content was done (fig. 2). The consistency of the content was thick mucoid fluid and around 800 ml of fluid was drained. Then flushing with normal saline and with betadine solution, cauterization with 2% silver nitrate was done. Then suturing was done with silk using simple interrupted sutures (fig.3). Post-operative care was done by using Intacef (500mg), Meloxicum (2ml) intramuscularly alongwith antiseptic dressing with betadine solution and sliversulfadiazine ointment for 5 days. The animal was advice to feed soft diet for 3 to 5 days. The animal recovered uneventfully and skin sutures were removed after 7 days. The case was closely followed for a

period of two months after the surgery, and there was no recurrence of the condition was reported.

Discussions

A salivary mucocele is an accumulation of saliva in a single or multilobated cavity lined with connective tissue, contiguous to a salivary gland or duct (Dunning, 2003). Salivary mucoceles, also known as sialoceles, salivary cysts and honey cysts, are thought to result from trauma to a salivary gland or duct resulting in leakage of saliva into the surrounding tissues. Clinically, a salivary mucocele is observed as an abnormal swelling containing saliva. The swelling is commonly observed in the cranial cervical or intermandibular, sublingual, or pharyngeal tissues hence cervical, sublingual, or pharyngeal mucoceles are used to describe these abnormal collections of saliva (Tobias, 2010). Dogs are more commonly affected than cats and although all breeds are susceptible, there are reports indicating that poodles, German shepherds, dachshunds, and Australian silky terriers are frequently affected (Knecht, 1998). Salivary mucoceles are not cysts. Cysts are cavities lined by epithelium, whereas the granulation tissue lining if a mucocele is produced secondary to inflammation caused by free saliva in the tissues (Yasonu *et al.*, 2011). It has been stated that the histopathologic appearance of mucoceles varies according to their stage of development. The actual cause is rarely identified; however choke collars, foreign bodies and sialoliths have been proposed in the literature. Most dogs have cervical or intermandibular mucoceles and usually are asymptomatic. These animals usually are presented for treatment with history of gradually developing, fluctuant, painless mass. Most mucoceles are soft and fluctuant whereas tumours and abscesses are generally firm. In this case, diagnosed of sialocele was made based on history, clinical signs and needle aspiration method. Blood tinged fluid and thick mucoid was aspirated from the swellings suggesting a sialocele. In the present case, complete drainage of the blood tinged fluid of sialocele and followed by cauterization with 2% silver nitrate was done. There was no complication and no recurrence was reported.

References

- [1] Hedlund, C.S. and Fossum, T.W. (2007). "Surgery of the oral cavity and oropharynx," in Small Animal Surgery, T.W. Fossum, Ed., Mosby, St. Louis, Mo, USA, 3rd edition, pp. 339–372
- [2] Dunning, D. (2003). "Oral cavity" in Textbook of Small Animal Surgery, D. Slatter, Ed., Saunders, Philadelphia, Pa, USA, 3rd edition, pp. 553–572

- [3] Knecht, C.D. (1998). “Salivary glands” in *Current Techniques in Small Animal Surgery*, M. J. Bojrab, Ed., Williams & Wilkins, Baltimore, Md, USA, 4th edition, pp. 183–186,
- [4] Tobias, K.M. (2010). *Manual of Small Animal Soft Tissue Surgery*, Wiley-Blackwell, Ames, Iowa, USA, pp
- [5] Benjamino, K.P., Birchard, S.J., Niles J.D. and Penrod, K.D. (2012). Pharyngeal mucoceles in dogs: 14 cases. *J. Am. An im. Hosp.Assoc.* 48(1):31-5.
- [6] Waldron, D. R and M. M. Smith (1991). Salivary mucoceles. *Probl.Vet.Med.* 3(2):270-6.
- [7] Yasonu, H., Nagai, H. and Ishimura, Y. (2011). Salivary mucocele in a laboratory beagle *Journal of Toxicologic Pathology*, 24:131–135.
- [8] Smith MM. (2000). Oral and salivary gland disorder. In: *Textbook of Veterinary Internal Medicine*. 5th edn. SJ Ettinger and EC Feldman, eds. WB Saunders Co. Philadelphia.pp.1119-1121.

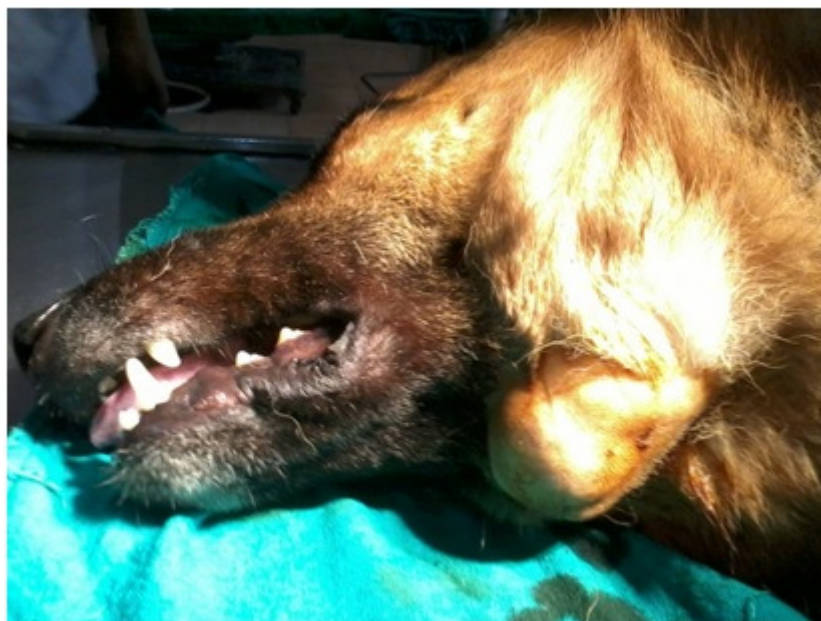


Fig. 1. Photograph showing swelling in intermandibular region

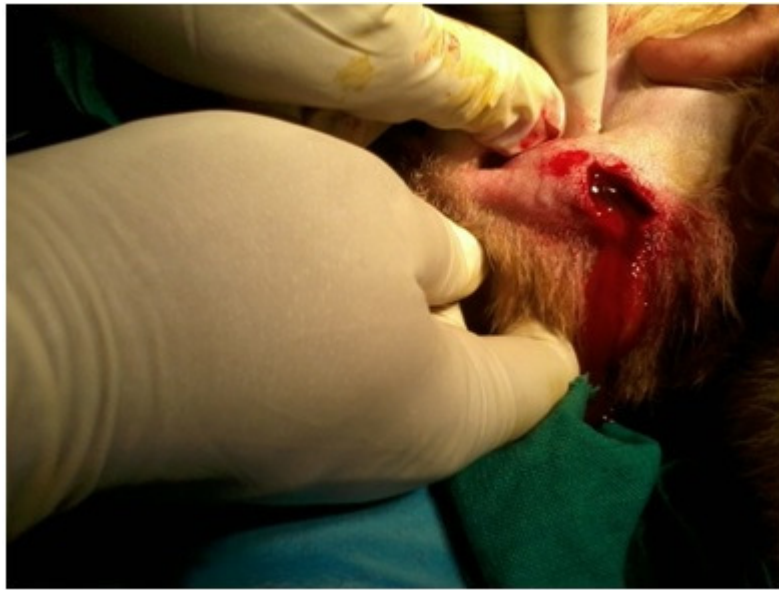

Fig. 2. Photographs showing drainage of the sialocele content (mucoïd and blood tinged fluid)

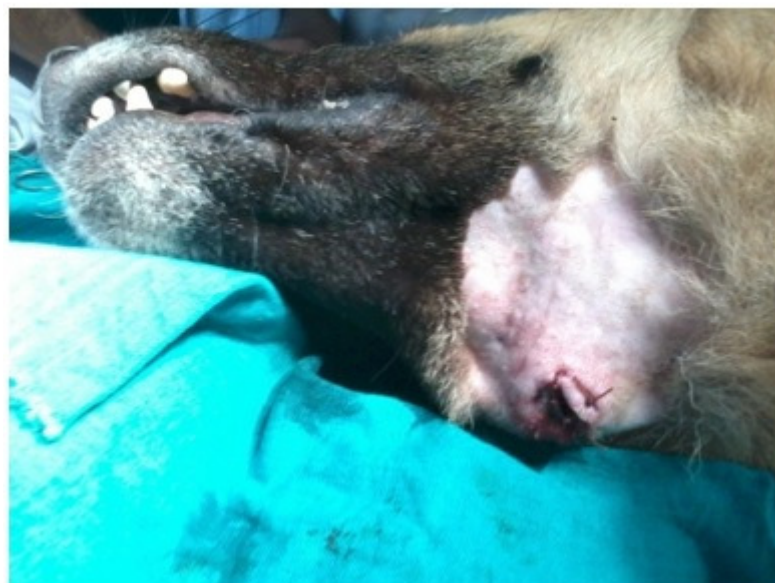

Fig. 3. Photograph showing post surgery