

DYSTOCIA DUE TO ATYPICAL SCHISTOSOMUS REFLEXUS FETUS IN A GRADED MURRAH BUFFALO

***K. Praveen Kumar¹, K. Manoj Kumar and M. Subbarayudu**

Department of Veterinary Gynaecology & Obstetrics, NTR College of Veterinary Science,
Sri Venkateswara Veterinary University, Gannavaram, Andhra Pradesh, INDIA– 521 102
E-mail: praveen.bvsc2@gmail.com (*Corresponding Author)

Abstract: This communication reports a case of atypical schistosomus reflexus syndrome in a pluriparous graded Murrah buffalo fetus.

Introduction

Schistosomus reflexus is a fetal monstrosity of coelosomian class most commonly seen in large animals and the defect inevitably cause dystocia (Noakes *et al.*, 2009). Typical Schistosomus reflexus observed in ruminants is characterised by ventral curvature of spinal cord, partial or complete exposure of abdominal viscera due to a fissure in the ventral abdominal wall, dorsal reflection of the ribs (Jobb and Kennedy 1963). The limbs are usually ankylosis and rigid (Roberts 1971) with positioning of the limbs adjacent to the skull and hypoplasia of lungs and diaphragm.

Key words: Buffalo, Dystocia, Schistosomus reflexus.

Case history and Observations

An eight years old graded Murrah buffalo carrying full term was referred to TVCC, NTR College of Veterinary Science, Gannavaram, Andhra Pradesh with a history of dystocia for the past 12 hours and appearance of head and forelimbs presented at the vulva. Clinical examination of the dam revealed normal rectal temperature with slight dehydration and lack of abdominal straining. Detailed obstetrical examination could not be performed due to lack of sufficient space as the fetus was jammed in the pelvic cavity with fully dilated cervix (Fig 1).

Treatment and discussion

Initially the dam was stabilized with the administration of inj. DNS- 5 liters I/V and placed into left lateral recumbency under low epidural anaesthesia (5 ml; 2% lignocaine hydrochloride). Percutaneous fetotomy was performed using scalpel to amputate the left

forelimb of foetus upto the elbow joint to get sufficient space. Deeper examination revealed the exposed abdominal viscera of the fetus. It was confirmed that ankylosed hindlimbs were the obstructing parts at the pelvic brim. Judicious mutation of the stifle joint by the obstetrician associated with alternate two point traction on ankylosed hindlimb by an assistant resulted in successful delivery of a relatively small sized dead male monster calf. Following delivery the animal was treated with strepto penicillin Inj (5 g IM x 5 days), dextrose normal saline (4 L, IV), Metronidazole Inj (1g IV), calcium borogluconate Inj (450 mL, slow IV), chlorpheniramine maleate Inj (15 mL, IM x 2 days), meloxicam Inj (15 mL, IM x 3 days), nitrofurazone 60mg+Urea 6g X 6 boli were placed inside the uterus and a herbal uterine cleanser was prescribed. The animal was discharged from the TVCC three hour after the treatment and an uneventful recovery was observed.

Anatomical observations of the delivered male monster fetus revealed mild dorsal deviation of the vertebral column; hence all the limbs (ankylosed) and head were not together as seen in cases of typical *Schistosomus reflexus* (Fig 2). Ventral abdominal wall was not completely closed with exposed viscera (Fig 3).

Summary

The present condition records a case of atypical *Schistosomus reflexus* (incomplete reflection of vertebral column) considering it as a congenital monster as a cause of dystocia. The cause could be genetic factor or teratogens or both.

References

- [1] Jubb, K.F. and Kennedy, P.C. (1963). *Pathology of Domestic Animals*, Academic Press, New York. Vol 1, pp. 6.
- [2] Noakes, D.E., Parkinson, T.J. and England, G.C.W. (2009). *Veterinary Reproduction and Obstetrics* 9th Edit., Edinburgh, London, U.K. pp. 217.
- [3] Roberts S J (1971). *Veterinary Obstetrics and Genital Diseases (Theriogenology)*. 2nd Edit., Published by the Author, Ithaca, New York. pp.70.




Fig 1: The dead fetus at dam's birth canal

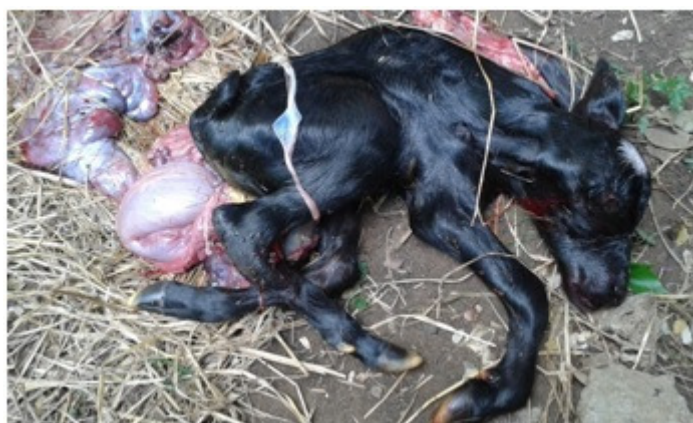

Fig 2: Dorsal deviation of vertebral column and ankylosis of the limbs

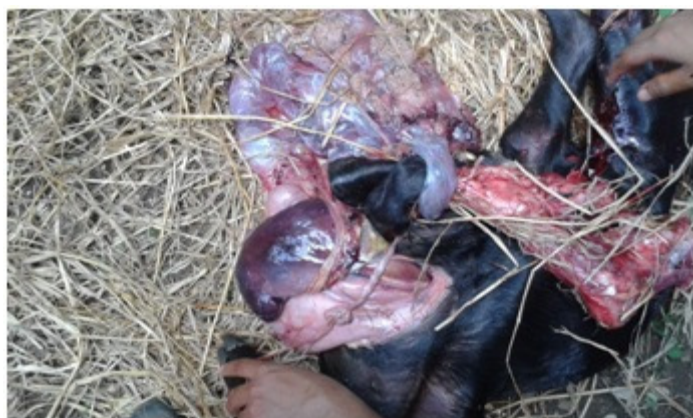

Fig 3: Exposed viscera of the fetus through abdominal fissure.