

## **SUCCESSFUL SURGICAL MANAGEMENT OF BILATERAL CORNEOCONJUNCTIVAL DERMOID CYST IN A CROSS BRED CALF- A CASE REPORT**

**\*M. Nagar, J.A. Quazi and S.K. Sharma**

Teaching Veterinary Clinical Complex

College of Veterinary and Animal Science, Navania, Vallabh Nagar, Udaipur

(Rajasthan University of Veterinary and Animal Sciences, Bikaner)

E-mail: nagarvet04@gmail.com (\*Corresponding Author)

**Abstract:** A six months old, cross bred calf presented with history of having solid skin like mass in both the eyes from birth and gradually increasing in size. It was diagnosed as congenital bilateral corneoconjunctival dermoid cyst based on history and clinical examination. Bilateral Corneoconjunctival dermoid cyst were removed by superficial lamellar keratectomy under the mild sedation and nerve block with local infiltration of anaesthesia. Temporary tarsorrhaphy performed and medial canthus area was leaving open for topical instillation of medicines. Post operatively broad spectrum antibiotic and anti-inflammatory was administered. Tarsorrhaphy sutures removed on 10<sup>th</sup> post-operative day and calf made uneventful recovery without reoccurrence.

**Keywords:** Calf; bilateral corneoconjunctival dermoid cyst; lamellar keratectomy.

### **Introduction**

Dermoid cyst is an uncommon developmental anomaly that has been reported in dogs, cats, horses, and cattle (Lawson, 1975). It may be solitary or multiple, firm to fluctuant, well circumscribed, smooth, and round and usually the overlaying skin is normal (Shields *et al.*, 1986). Dermoid cysts are formed due to defective epidermal closure along embryonic fissures, which isolates an island of ectoderm in the dermis or subcutis. The cyst usually contains hair, keratin, and sebum, and these materials may produce progressive enlargement of the structure so that it becomes clinically apparent (Edwards, 2002).

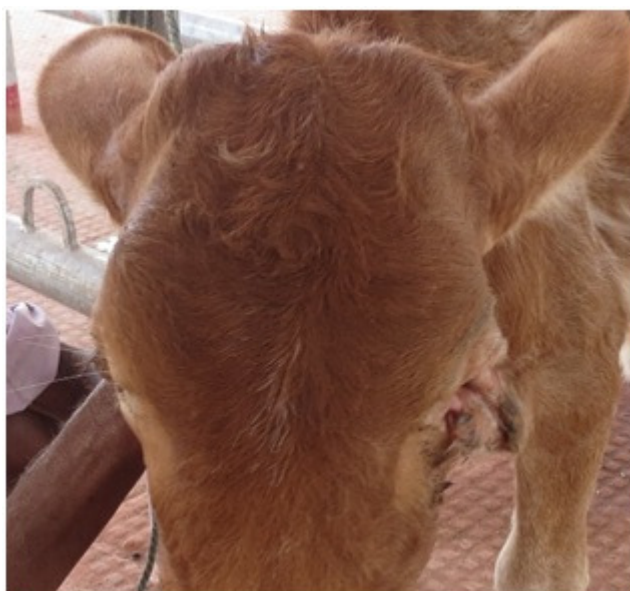Ocular dermoid occurred rarely in newborn calves. Seldom it associate with other congenital eye defects like corneal opacity, which have been described in Holsteins as recessive condition (Deas, 1959). Ocular dermoids have not been demonstrated to be inherited in bovine, nevertheless their occurrence are recommended to be duly noted in breeding herds and affected animals should be treated. Yeruham *et al* (2002) reported Corneal dermoid, Corneoscleral dermoid, Corneoconjunctival dermoid and Conjunctival dermoid are the forms

of ocular dermoid in dairy cattle herds. Ocular dermoids are skin or skin like appendages that arise on the usually limbus, conjunctiva and cornea (Ismail, 1994). Dermoids occurs sporadically in numerous cattle breeds and can be unilateral or bilateral (Williams and Gelattk, 1981). These tissues or hair follicles usually irritate the eye and animal suffer from chronic epiphora, conjunctivitis and keratitis and may cause visual impairment (Pandey *et al*, 2011).

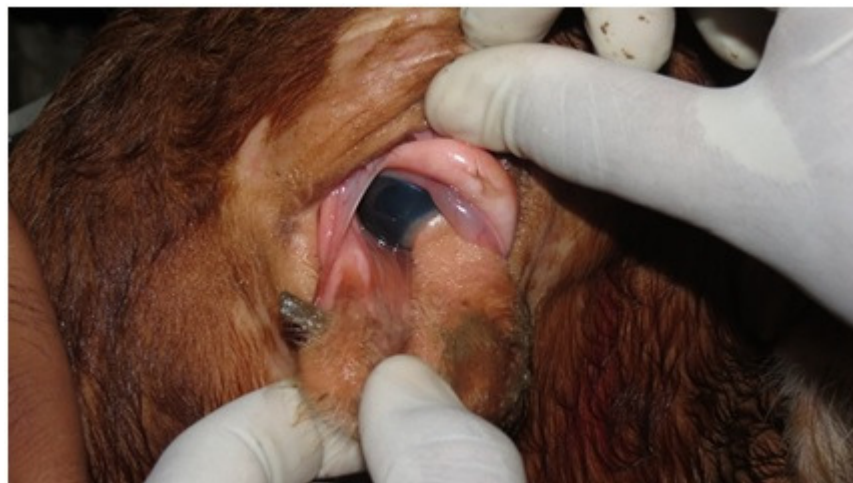In present communication, we describe the Successful management of bilateral Corneoconjunctival dermoidcysts in a cross breed calf.

### **History and Observation**

A six months old cross bred calf presented with history of having solid skin like mass in both the eyes from birth and gradually increasing in size. Calf having severe lacrimation from past two months and do not gain weight. Clinical examination of both the eyes revealed mild blepharospasm, epiphora, conjunctivitis and having solitary, firm, well circumscribed, smooth, round cysts. Overlaying skin of cysts was normal, containing hairs (fig. 1). Cysts of both the eyes were involved included ventro-laterallimbus, third eyelid, medial canthus, eyelid and bulbar conjunctiva (fig. 2). These were diagnosed as dermoid cysts based on history and clinical examinations.



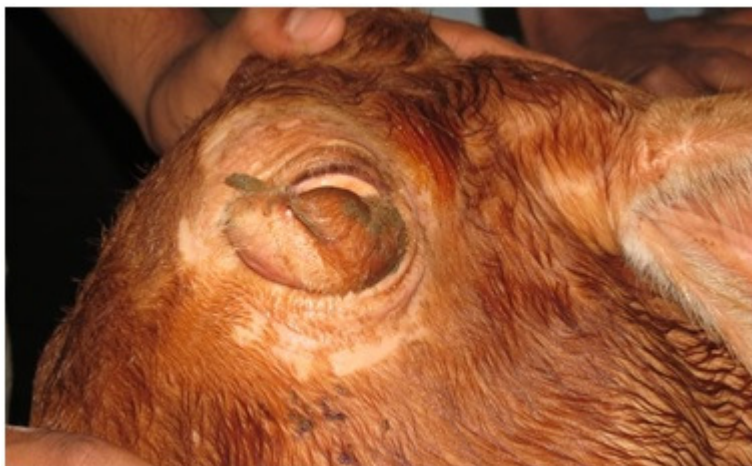**Fig. 1** Overlaying skin of cysts is normal, containing hairs.



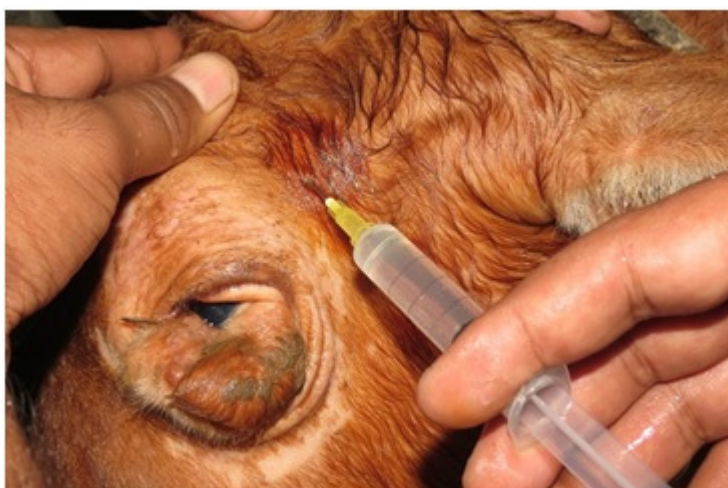**Fig. 2** Cysts involved included ventro-lateral limbus, third eyelid, medial canthus, eyelid and bulbar conjunctiva

### **Treatment**

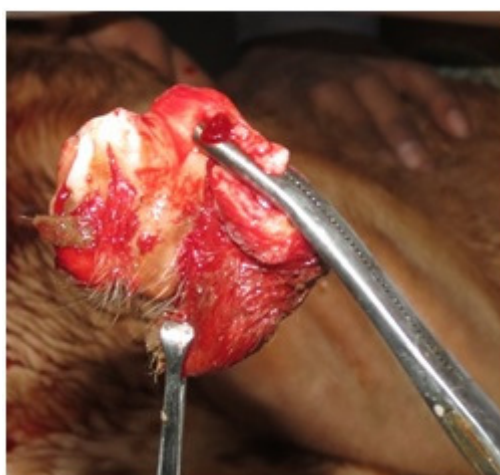After clinical examination, calf was prepared for surgical excision of dermoids cysts. Both the eyes prepared for aseptic surgery by shaving, scrubbing and application of mild antiseptic solution (fig. 3). The calf was sedated with xylazine hydrochloride at 0.1 mg/kg IM and restrained on table in lateral recumbency. Auriculopalpebral and Peterson nerve block and Local infiltration with 2% lignocaine hydrochloride was performed (fig. 4). The dermoidcysts were excised by superficial lamellar keratectomy that was extended into the third eyelid, medial canthus, eyelid and bulbar conjunctiva (fig. 5). Cysts were carefully dissected from all adherent areas, stalks were ligated with chromic catgut no. 2/0 (fig. 6). Temporary tarsorrhaphy performed and medial canthus area was leaving open for topical instillation of medicines (fig. 7). Postoperatively, systemic amoxicillin and cloxacilin 1 gm were administered IM for five days in addition to a local antibiotic and anti-inflammatory (for eye instillation). Tarsorrhaphy sutures removed on 10<sup>th</sup> post-operative day. The calf recovered uneventfully. The calf was again examined after one month for rule out any reoccurrence. Re-examination after one month did not reveal any re-occurrence of dermoid cysts.



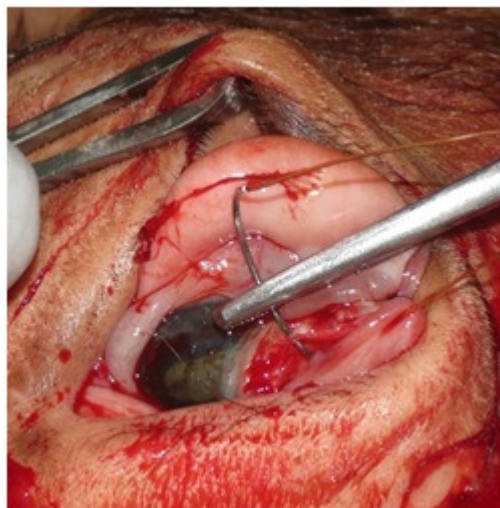
**Fig. 3** Prepared eye for aseptic surgery



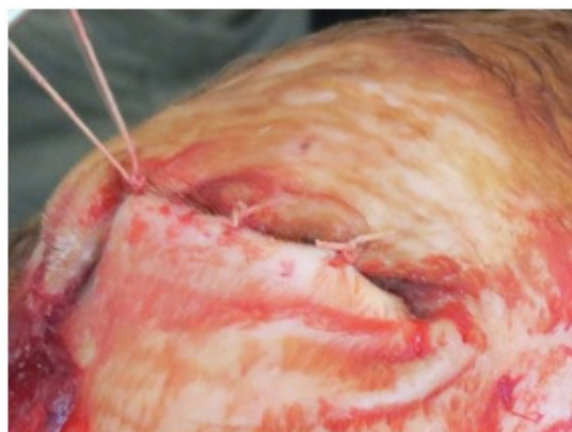**Fig. 4** performing nerve block



**Fig. 5** excised cyst



**Fig. 6** Stalk ligating with chromic catgut



**Fig. 7** Performing temporary tarsorrhaphy

### **Discussion**

Yeruham *et al* (2002) reported Corneal dermoid, Corneoscleral dermoid, Corneoconjunctival dermoid and Conjunctival dermoid are forms of ocular dermoid in dairy cattle herds. The incidence is estimated by 0.002%. This congenital anomaly seems not to be inherited, but it may appear with other congenital eye defects or with other malformations. In present case also reported corneoconjunctival form of dermoid that was not hereditary.

Corneoconjunctival dermoids are skin or skin like appendages that arise on the usually limbus, conjunctiva and cornea (Ismail, 1994). Dermoids occurs sporadically in numerous cattle breeds and can be unilateral or bilateral (Williams and Gelattk, 1981). These tissues or hair follicles usually irritate the eye and animal suffer from chronic epiphora, conjunctivitis and keratitis (Pandey *et al*, 2011). Ocular dermoids have been reported and corrected

surgically earlier in canines (Dice, 1980), felines (Roberts and Lipton, 1975), bovines (Shiju *et al*, 2010) and many other farm animals (Ismail, 1984).

### Conclusion

Successful management of bilateral corneoconjunctival dermoid cyst in a cross bred calf by superficial lamellar keratectomy that was extended into the third eyelid, medial canthus, eyelid and bulbar conjunctiva.

### References

- [1] Deas D.W. (1959). A note hereditary opacity of the cornea in British Friesian cattle. *Vet. Rec.*, **71**, 619-620.
- [2] Dice, P.F. (1980). Primary corneal disease in the dog and cat. *Vet Clin North Am [Small Anim Pract]* **10**: 339-356.
- [3] Edwards, J.F. (2002). Three cases of ovarian epidermoid cysts in cattle. *Vet. Pathol.* **39** (6), 744-746.
- [4] Ismail, S.F. (1994). Ocular dermoid in some farm animals. *Assiut. Vet. Med. Journal*, **30**. 212-20.
- [5] Lawson, D.D. (1975). Corneal dermoids in animals. *Vet. Rec.* **97** (23), 449-450.
- [6] Pandey, S.S., Bharti, B., Patidar, A. and Shukla, N. (2011). Surgical correction of corneal dermoid in a cross bred calf. *Veterinary Practitioner* **12**:1:-33.
- [7] Roberts, S.R. and Lipton (1995). *The eye in feline medicine surgery*. Cattcot, E, J, ed 2<sup>nd</sup> eds, American Veterinary Publication, Inc USA Pp. 485-518.
- [8] Shields, J.A., Laibson, P.R., Augsburger, J.J. and Michon, C.A. (1986). Central corneal dermoid: a clinicopathologic correlation and review of the literature. *Can. J. Ophthalmol.* **21** (1), 23-26.
- [9] Shiju, S., M.B. Justin William, G.D. Rao, R. Shivashankar and Suresh Kumar (2010). Congenital malformation in ruminants and its surgical management. *Veterinary World* **3**(3): 118-119.
- [10] Williamsl, W.; Gelattk, N. (1981). *Food animal ophthalmology*. **In:** *Textbook of Veterinary Ophthalmology*, ed. Gelatt, pp. 606-648. Lea and Febiger, Philadelphia.
- [11] YeruhamI., Perl S. and Liberboim M. (2002). Ocular dermoid in dairy cattle - 12 years survey. *Revue Méd. Vét.*, **153**, 2, 91-92.