

## UTERINE LIPOSARCOMA IN A COW-A CASE REPORT

\*Nasreen A<sup>1</sup>, Sailaja. N<sup>2</sup>, Ch. Srilatha<sup>1</sup>, B. Sreedevi<sup>3</sup>, K. Padmaja<sup>4</sup> and N. Jayasree<sup>1</sup>

<sup>1</sup>Department of Veterinary Pathology, College of Veterinary Science, Tirupati

<sup>2</sup>CCVEC, SVVU, Tirupati

<sup>3</sup>Department of Veterinary Microbiology, College of Veterinary Science, Tirupati

<sup>4</sup>Department of Veterinary Biochemistry, College of Veterinary Science, Tirupati

E-mail: nashreen7@gmail.com (\*Corresponding Author)

**Abstract:** Uterine tissue sample was collected from a cow during post mortem examination. Grossly, greatly thickened myometrium with small gelatinous raised areas in the mucosa was noticed. Cytology revealed the presence of lipoblasts. Histopathologically numerous pleomorphic lipoblasts were seen in the submucosa of the uterus. Based on gross, cytology and histopathology present case is diagnosed as liposarcoma.

**Keywords:** Cow, cytology, histopathology, liposarcoma.

### Introduction

Liposarcomas are rare malignant tumours of white adipose cell lipoblasts [1]. They are considered a soft tissue neoplasm because of their mesenchymal or connective tissue cell origin. They often arise from the skin and subcutis [2]. Most reports indicate that liposarcomas are unlikely to metastasize; however, a few published reports suggest that liposarcomas are aggressive, locally invasive, and commonly metastasize to the lungs, liver, and bone [3]. Incidence of uterine neoplasia is 52.05% Murrah buffaloes [4]. Liposarcomas had a variegated fleshy, tan, myxoid, and necrotic sectioned surface [5]. Tumours of the genital system are usually detected during necropsy [6,7]. Clinical signs are dependant on the size and location of the tumour. As per the previous studies, adenocarcinoma was the most common tumour in the uterus of cattle [8]. This paper discusses about a case report of uterine liposarcoma in a cow.

### Case history

Uterine tissue from a carcass of an adult cow was collected at necropsy in College of Veterinary Science, Tirupati. Impression smears from cut section of uterus were collected and stained with Leishman stain. Representative tissue pieces were fixed in 10% neutral buffered formalin for histopathological examination. Tissue sections of 5-6µ were made and stained with hematoxylin and eosin method [9].

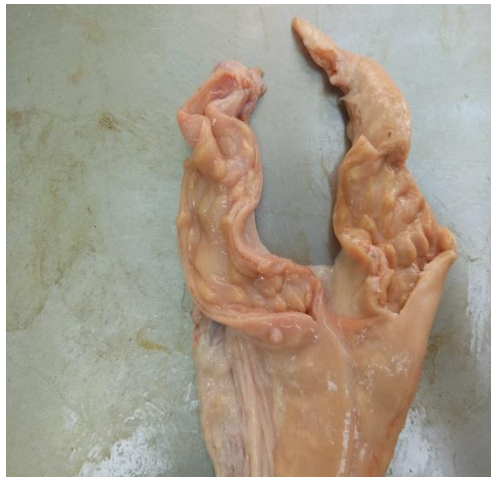## Results and discussion

Upon macroscopic examination, the uterine wall appeared greatly thickened with small gelatinous raised areas in the mucosa especially at the caruncular area [fig1]. Impression smears revealed large cells having varied sized lipid droplets in the cytoplasm with a flattened nucleus pushed to one side [fig 2].

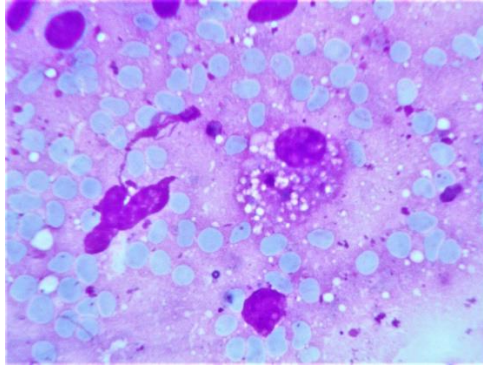
On histopathological examination, numerous pleomorphic lipoblasts were seen in the sub epithelial and submucosal region [fig 3, 4]. The lipoblasts were characterized by presence of a single large cytoplasmic vacuole and flattened hyperchromatic nucleus with nucleoli. The proliferating cells were seen encircling the glandular structures in the sub mucosa.

Liposarcomas are rare tumours compared to lipomas in domestic animals [10]. Histopathological features of lipocytes having clear intracytoplasmic vacuoles with centrally placed round nucleus [11]. Liposarcomas may possibly arise from misplacement of an embryonic progenitor cell or from metaplasia of mesenchymal tissues and perivascular adipocytes [12,13] Liposarcoma might also occur due to recurrent trauma [14]. There is association of retroviral infection for the development of liposarcoma in dogs [15]. Based on above findings the present case is diagnosed as liposarcoma in uterus.

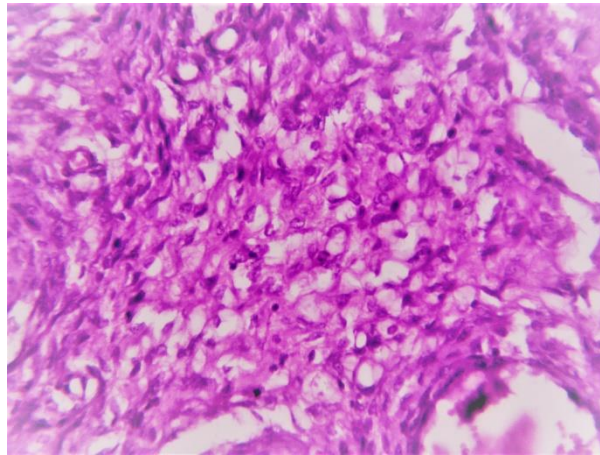
**Fig 1 small gelatinous raised areas in the mucosa of uterus**



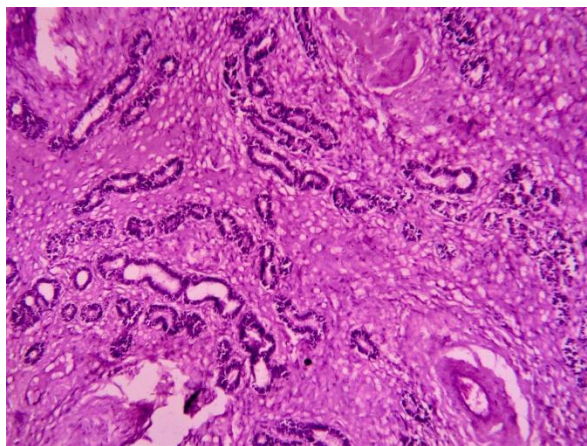
**Fig 2 large cell having varied sized lipid droplets in the cytoplasm with a flattened nucleus pushed to one side-LeishnmannX1000**



**Fig 3 pleomorphic lipoblasts were seen in the submucosal region H&EX450**



**Fig 4 Lipoblasts with encircling the glandular structures H&EX 40**



## References

- [1] K. V. F. Jubb, P. C. Kennedy and N. C. Palmer, "Female Genital Tract," Pathology of Domestic Animals, 5th Edition, Elsevier Saunders, 2007.

- [2] D.A. Fiorito, "Hyperestrogenism in Bitches," *Compendium on Continuing Education for the Practicing Veterinarian*, Vol. 14, 1992, pp. 727-729.
- [3] W.B. Morrison, "Cancer of the Reproductive Tract," *Cancer in Dogs and Cats: Medical and Surgical Management*, 2nd Edition, TNM Publishing, 2002.
- [4] Anusha K, Mouli Krishna K and Srilatha Ch 2015 Uterine Adenocarcinoma in Abattoir Genitalia of Buffaloes. *Indian Vet. J.*, 92 (5): 95 – 97.
- [5] Levin Pascale Hummel, Wei, Xiao-Jun, Gagner, Jean-Pierre, Flax, Herschel, Mittal, Khush Blank, Stephanie V 2003 Pleomorphic Liposarcoma of the Uterus: Case Report and Literature Review *International Journal of Gynecological Pathology*: October 2003 - Volume 22 - Issue 4 - p 407-411.
- [6] F.J. Pena, J. A. Gines, J. Duque, R. Martinez-Pe're, L. Madejo, I. N. Martinez, J.M. Moran and S. FernandezGarcia, "Endometrial Adenocarcinoma and Mucometra in a 6 Years Old Alaska Malamute Dog," *Reproduction in Domestic Animals*, Vol. 41, No. 2, 2006, pp. 189-190. doi:10.1111/j.1439-0531.2006.00645.x
- [7] K. Eker, M. R. Salmanoglu and S. A. Vural, "Unilateral Leiomyoma in the Mesosalpinx of a Dog," *Journal of the American Animal Hospital Association*, Vol. 42, 2006, pp. 392-394.
- [8] Jones TC, Hunt RD, King NW (1997) Genital System. pp. 1170–1172. In: *Veterinary Pathology*, 6th ed., Williams and Wilkins, Baltimore.
- [9] Culling CFA (1974) *Hand Book of Histopathological and Histochemical Techniques (Including Museum Techniques)* 3rd Edition 361.
- [10] Pulley LT and Stannard AA 1990 Tumors of the skin and soft tissues in *Tumors of Domestic Animals*, Moulton, University of California Press, Berkeley, Calif, USA, 3rd edition. 45-48.
- [11] Cecilia V, Marco R, Francesca M, Gary ECW and Giuseppe C 2013 Uterine liposarcoma in a German shepherd dog. *Open J. Vet. Med.*, 3: 91-94.
- [12] Brandfass RT and Everts-Suarez EA 1955 Lipomatous tumors of the uterus: a review of the world's literature with report of a case of true lipoma. *American J. Obstet. Gynecol.*, 70: 359–367.
- [13] Fadare O, Zheng W, Crispens MA, Jones HW, Khabele D, Gwin K, Liang SX, Mohammed K, Desouki MM, Parkash V and Hecht JL 2013 Morphologic and other clinicopathologic features of endometrial clear cell carcinoma: a comprehensive analysis of 50 rigorously classified cases. *American J. Cancer Res.*, 3(1): 70-95.

[14] Dubin MR and Chang EW 2006 Liposarcoma of the tongue: case report and review of the literature. *Head & Face Med.*, 26: 2–21.

[15] Stephens LC, Tsai CC, Raulston GL and Jardine JH 1983 Virus-associated liposarcoma and malignant lymphoma in a kitten. *Journal of the American Vet. Med. Assoc.*, 183: 123–5.