

TRAUMATIC ULCERATIVE ABOMASITIS WITH UNUSUAL FOREIGN BODIES IN ABOMASUM OF A COW- NECROPSY

***Narote S.R., Moregaonkar S.D., Gangane G.R., Tandale R.U.,
Chavan P.A. and Shete H.J.**

Department of Veterinary Pathology,
College of Veterinary and Animal Sciences, VNMKV Campus, Parbhani- 431402 (MS)
Maharashtra Animal and Fishery Sciences University, Nagpur (MS)
E-mail: satishnarote155@gmail.com (*Corresponding author)

Abstract: Ingestion of indigestible foreign bodies in cattle is a pathological condition important from both economic and health point of view. It has mostly been reported in association with feed scarcity. This necropsy report also deals with the same. An 8 yrs old non-descript cow carcass with the history of anorexia, constipation, tympany and pica was presented for necropsy examination, which revealed different types of foreign bodies such as sand particles, pieces of aluminum wire, broken bangles, broken glasses and pieces of hard plastics in the abomasum. In rumen also, there were 2-3 pieces of nylon rope, polyethylene bags and pieces of aluminum wire observed. The presented gross lesions in the abomasum were suggestive of traumatic ulcerative abomasitis.

Keywords: Foreign bodies, tympany, abomasum, traumatic ulcerative abomasitis.

Introduction

Ingestion of indigestible foreign materials by cattle and buffaloes is a common problem worldwide, known as foreign body syndrome (FBS). Incidence of foreign body syndrome in bovine species has been increasing day by day. This syndrome is more common in bovine than in small ruminants because they do not use their lips for prehension and are more likely to eat chopped feed (Ashfaq *et al.*, 2015). Moreover, indiscriminate feeding habits, feed scarcity, industrialization and mechanization of agriculture, environmental pollution are some of the predisposing factors for FBS. The non-metallic foreign body syndrome is a silent killer disease resulting from ingestion of polywastes, rubber, plastics, leather materials, ropes, clothes and cement bags (Reddy and Sasikala, 2012; Abu-Seida and Al-Abbadi, 2016). The long-term consumption of sand or soil-laden feed and water or the consumption of sand or soil by animals with deficiency of trace element and minerals both lead to the accumulation of sand in the abomasum (Cebra *et al.*, 1996; Simsek *et al.*, 2015).

*Received May 6, 2019 * Published June 2, 2019 * www.ijset.net*

Case history and necropsy findings:

An 8 yrs old non-descript cow carcass was presented for necropsy examination to the Department of Veterinary Pathology, with the history of anorexia, constipation, tympany and pica.

On external examination, carcass appeared to be weak, debilitated and dehydrated with rough hair coat. The internal examination of the presented carcass showed gross lesions suggestive of traumatic ulcerative abomasitis with diffuse congestion, haemorrhages and focal ulcerative lesions on abomasal mucosa (Fig. 1). In the abomasum, different types of unusual foreign bodies such as sand particles, pieces of aluminum wire, broken bangles, broken glasses and pieces of hard plastics were observed (Fig. 2 & 3) whereas, in rumen, 2-3 pieces of nylon rope, hard plastics, polyethylene bags and pieces of aluminum wire were also observed (Fig. 4). Because of continuous irritation by these foreign bodies, abomasal mucosa showed diffuse congestion and haemorrhages, which in turn into ulcerative lesions.

The other necropsy lesions recorded were hydropericardium, focal ecchymotic haemorrhages on epicardium, congestion of right lung with pneumonic areas at places, diffuse petechial haemorrhages on kidney and fragile liver with rounding of its borders.

Discussion

Presence of foreign bodies in the abomasum results in abomasal impaction resulted into abomasal distention secondary to luminal foreign bodies, including plastic bags, leather material, sand particles, rope and trichobezoars. It is reported that abomasal impaction is rarely encountered in cattle and associated with traumatic reticuloperitonitis (Pope, 1961; Nepal and Edwards, 1968), vagal indigestion, adhesions of the abomasum with the rumen or the ventral part of the abdominal wall, and the consumption of non-food material such as sand, gravel etc. (Erickson and Hendrick, 2011). In conclusion, considering history of inanition, anorexia, papery white mucosa of eyes (indicating anemia) and pica along with weak and debilitated appearance, animal might have died due to cardio-respiratory failure consequenced by nutritional deficiency, resulted due to traumatic ulcerative abomasitis.

References

- [1] Abu-Seida, Ashraf M. and Oday S. Al-Abbadi (2016) Recent Advances in the Management of Foreign Body Syndrome in Cattle and Buffaloes: A Review. *Pakistan Vet J.* 36(4): 385-393.

- [2] Ashfaq M, Razzaq A, Hassan S and ul Haq S (2015) Factors affecting the economic losses due to livestock diseases: a case study of district Faisalabad. *Pak J. Agri. Sci.*, 52: 515-520.
- [3] Cebra C., Cebra M., Garry F. (1996) Gravel obstruction in the abomasum or duodenum of two cows. *J.A.V.M.A.*, 209: 1294-1296.
- [4] Devi Prasad, V., P. Ravi Kumar, NVV Harikrishna and D. Bhagyaraju (2017) Traumatic reticulitis, reticulo-peritonitis and pericarditis (Foreign body syndrome) in bovines. *J. Livestock Sci.*, 8: 98-102.
- [5] Erickson and Hendrick (2011) Sand impactions in Saskatchewan beef cow-calf herd. *Can. Vet. J.*, 52: 74-76.
- [6] Nepal PA and Edwards GB (1968) "Vagus indigestion" in cattle. *Vet Rec*, 82: 396-402.
- [7] Pope DC (1961) Abomasal impaction of adult cattle. *Vet. Rec.*, 73:1174-1177.
- [8] Reddy MV and Sasikala P (2012) A review on foreign bodies with special reference to plastic pollution threat to livestock and environment in Tirupati rural areas. *Int. J. Scient. Res. Pub.*, 2: 1-8.
- [9] Simsek, A., S. Sekin, H. Icen, A. Kochan, OY Celik, T. Yaman (2015) Abomasal impaction due to sand accumulation in two cows. *Large Ani. Review*, 21: 125-127.

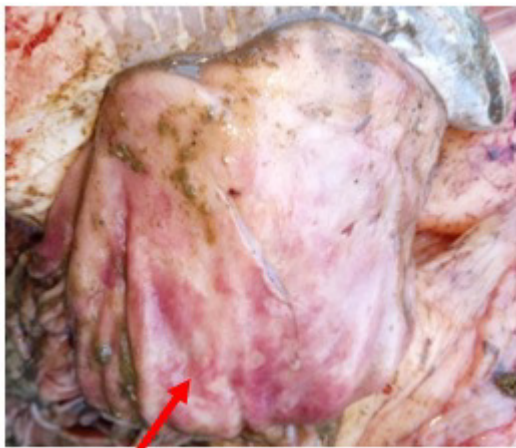


Fig. 1: Traumatic ulcerative abomasitis with diffuse congestion, haemorrhages and focal ulcerative lesions

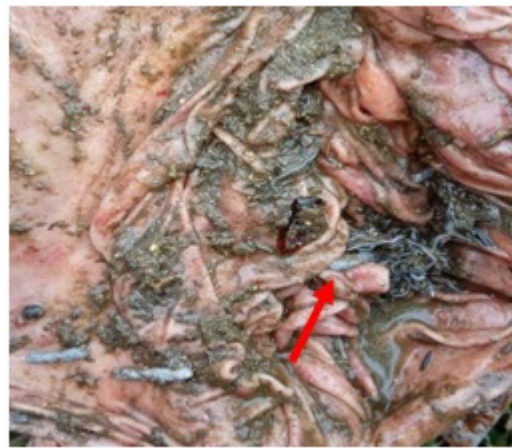

Fig. 2: Presence of foreign bodies in the lumen of abomasum



Fig. 3: Recovered foreign bodies from abomasum (sand particles, pieces of aluminum wire, broken bangles and broken glasses)

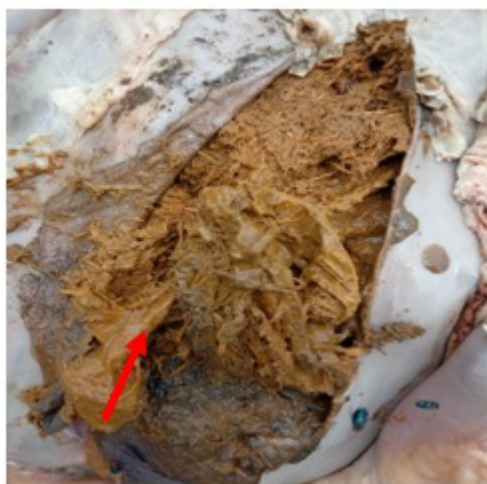

Fig. 4: Presence of foreign bodies in rumen