

Case Report

SNAKE BITE IN BUFFALO-A CASE REPORT

**Tandale R.U.¹, S.D. Moregaonkar, G.R. Gangane, S.R. Narote and P.A. Chavan
and A.N Choudhari**

Department of Veterinary Pathology,
College of Veterinary and Animal Sciences, Parbhani, (431402),
Maharashtra Animal and Fishery Sciences University, Nagpur, (440006)

Abstract: This clinical article reports a case of snake bite in four year old buffalo. In the present study pathological investigations were carried out. Buffalo had a history of swelling at face region with snake bite mark above right nostril, salivation, restlessness followed by death. Gross and histopathological lesions observed in a affected buffalo were suggestive of snake bite.

Keywords: Hemorrhages, Snake bite, Viperidae family.

Introduction


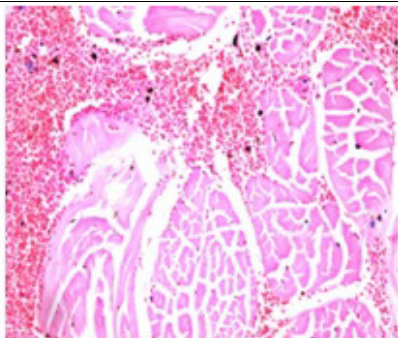

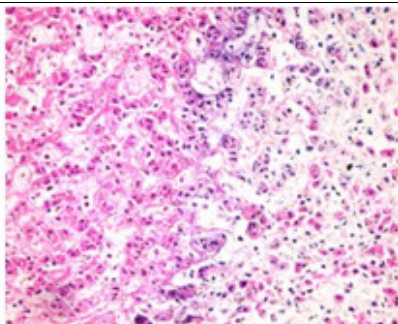

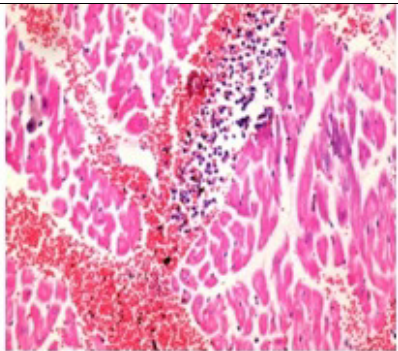
In India, snake bite is an important and common cause of accidental death in livestock. The literature scanned could not revealed the exact data on deaths being caused by snake bite in livestock. However, this is very common death cause in animals. In India, there are nearly 200 species of snake, among them the common venomous snakes encountered are the Indian Cobra (*Naja naja*) which is neurotoxic (Vani Prasad and Koley, 2006), Common Krait (*Bungarus caeruleus*) and the Russell's Viper (Thangapandiyan *et al.*, 2013 and Kamdi *et al.*, 2013). In animals most of the cases remains unnoticed even then died of snake bite. Therefore, present case had been studied to record pathological findings in a buffalo died of snake bite.

Material and method

A four year She buffalo carcass was presented for necropsy examination at Department of Veterinary Pathology, College of Veterinary and Animal Sciences, Parbhani.

With the history that while grazing animal suddenly developed salivation, respiratory distress, epistaxis, swollen face and restlessness. The She buffalo was first treated by local Veterinarian and then brought to Teaching Veterinary Clinical Complex (TVCC), Parbhani. However, prior to start any treatment at TVCC suddenly buffalo died.

*Received May 6, 2019 * Published June 2, 2019 * www.ijset.net*

		<p>Fig. 1: Fang mark (arrow), edematous swelling on face and epistaxis in affected buffalo.</p> <p>Fig. 2: Diffuse areas of hemorrhages at the site of snake bite.</p> <p>Fig. 3: Petechial to ecchymotic haemorrhages in affected musculature.</p> <p>Fig. 4: Section of muscle from an area of snake bite showing multifocal, ecchymotic hemorrhages and mild to focal myonecrosis (H & E X 400).</p> <p>Fig. 5: Section of liver showing moderate necrotic changes in hepatic parenchyma with moderate infiltration of inflammatory cells (H & E X 400).</p> <p>Fig. 6: Section of heart with multifocal, ecchymotic linear haemorrhages with multifocal inflammatory cell infiltration (H & E X 400).</p>
<p>Figure 1</p>	<p>Figure 4</p>	
		
<p>Figure 2</p>	<p>Figure 5</p>	
		
<p>Figure 3</p>	<p>Figure 6</p>	

A through necropsy examination was conducted and tissue samples of swollen face region, heart and liver were collected in 10% formalin for histopathological examination. The tissue samples were subjected for histopathology as per standard procedure described by Luna (1968).

Results and Discussion

Gross lesions

During clinical examination, snake bite mark just above right nostril were observed along with generalized facial edema and epistaxis (Fig.1). On post-mortem examination, the

carcass revealed swollen face with severe cyanotic conjunctival mucus membranes. On reflection of skin of face region, the subcutaneous muscle showed extensive oedema and hemorrhages (Fig.2). The tracheal mucosa was severely congested and there was frothy exudate in the tracheal lumen. Liver and Kidneys were enlarged, fragile and pale. Lung showed congestion with mild oedema. The right chamber of heart was dilated. Intestinal mucosa appeared to be haemorrhagic and spleen was shrunken. There were multifocal petechial to echymotic haemorrhages on epicardial and endocardial surfaces of heart (Fig.3).

Histopathology

Sections of affected muscle from area of snake bite showed multifocal, ecchymotic intramuscular hemorrhages and mild to focal myonecrosis (Fig.4). Moderate necrotic changes in hepatic parenchyma with inflammatory cell infiltration were also noticed (Fig.5). Section of heart showed multifocal ecchymotic linear hemorrhages with multifocal inflammatory cell infiltration (Fig.6).

On the manifestation of history, clinical signs and post mortem lesions, it was concluded that the she buffalo died of snake bite.

Discussion

The gross and histopathological observations noted in the present case of snake bite are in consonance with the pathological changes reported earlier, by (Radostits *et al.*, 2009; Banga *et al.*, 2009 and Farooq *et al.*, 2014) in viper bites. They reported swelling at the site of bite, haemolysis, myonecrosis, subcutaneous edema, ecchymotic hemorrhages and death. However, myoglobinuria, flaccid paralysis, papillary dilation, trembling gait and wound also been observed in the snake bite case.

The effect of snake bite depends upon the size and species of the snake, the size of the bitten animal and the location of the bite, particularly with reference to thickness of hair coat and the quantity of subcutaneous fat (Radostits *et al.*, 2009). Farm animals are more likely to be bitten on jaw (Banga *et al.*, 2009) as was also observed in the present study.

REFERENCES

- [1] Banga H.S., R.S. Brar, S.G. Chavhan, H.S. Sandhu and A.M. Kammon (2009) Pathology of Snake Bite in Cow. *Toxicol. Int.*, **16**(1):69-71.
- [2] Farooq, U., H. Irshad, R.W. Ullah, A. Ullah, M. Afzal, A. Latif and A.B. Zahur (2014) Snake Bite in Jersey Cattle; a Case Report. *Res. J. for Vet. Practitioners*, **2**(5): 82-83.
- [3] Kamdi B.P., N.G. Shrikande, R. Pande, R. Padole, P.M. Sonkusale and A.G. Bhandarkar (2013) Pathology of Snake Bite in Stray Dog. *J. of Agri. and Vet. Sci.*, **5**(3): 27-28.

- [4] L.G. Luna, (Manual of Histochemical Staining Methods of Armed Forces Institute of Pathology, 3rd edn. Mc Graw Hill Book Co. New York, 1968).
- [5] Radostits O.M., C.C. Gay, K.W. Hinchcliff and P.D. Constable (2009). Veterinary Medicine, 10th ed. Elsevier: 1916-1918.
- [6] Thangapandiyan M., T. Mohanapriya, R. Sridhar, B. Murali Manohar and C. Balchandran (2013) Pathology of Snake Envenomation in a Dog. The Indian Vet. J., **90**(5): 119-120.
- [7] V. Vani Prasad, and K.M. Koley, (Synopsis of Veterinary Phormacology and Toxicology, 1stedn. Vahini Publications, 2006) 324-325.