

## **OUTBREAK OF FOOT AND MOUTH DISEASE ASSOCIATED WITH ABORTION AMONG SHEEP IN SAUDI ARABIA**

**M. Hamouda<sup>1\*</sup>, A. Jazzar<sup>1</sup>, I. EL-Sabagh<sup>2</sup> and Abdulkarem Al-Shabebi<sup>3</sup>**

<sup>1</sup>Department of Pathology, <sup>2</sup>Central Biotechnology Laboratory, <sup>3</sup>Department of Anatomy,  
College of Veterinary Medicine, Faisal University, Saudi Arabia

E-mail: mhamouda@kfu.edu.sa (\* *Corresponding author*)

**Abstract:** This study was carried out to assess clinical, histopathology and PCR of foot and mouth disease (FMDV) in indigenous sheep. A sheep farm was attacked with virus during summer season. The clinical signs were fever, nasal discharge, erosive stomatitis and lameness. A total of 6 aborted lambs was submitted for necropsy at Department of Veterinary Pathology. A thorough postmortem examination of lambs was performed and all internal organs were carefully examined. There were grayish white necrotic foci on ventricular walls of the myocardium in all aborted lambs, which is considered a regular and prominent finding. Histopathology revealed necrotising myocarditis with hyaline degeneration as well as infiltration of lymphocytes and macrophages. Oral swabs from adult sheep and tissue samples from myocardium, liver, kidney and intestine from aborted lambs were collected and processed for PCR. In conclusion, FMDV in indigenous sheep was transmitted vertically to fetuses and associated with abortion.

**Keywords:** FMDV, sheep, abortion.

### **INTRODUCTION**

Foot and Mouth Disease (FMD) is a highly communicable disease which can be categorized within Aphthovirus genus as a member of the Picornaviridae family (Belsham, 1993). The disease affects cattle, Alexandersen *et al.* 2003; Grubman *et al.* 2004). FMD is a highly transmissible disease during the clinical phase of infection (Charleston *et al.* 2011; Orsel *et al.* 2009).

The spread of the disease is occurring mainly by direct contact and may occur mechanically from infected to susceptible animals. (Alexandersen *et al.* 2003; Stenfeldt *et al.* 2015). FMDV in sheep and goat is usually inapparent and milder than in cattle and other animals (Hemanth *et al.* 2014). However, the most clinical signs in sheep are agalactia in ewes, vesicles in the interdigital space as well as oral lesion which is less common on tongue, gums and dental pad (Barnett and Cox, 1999; Hughes *et al.* 2002). The disease is not often fatal in adult sheep, but is frequently of high mortality in lambs due to myocarditis (Barker *et al.* 2005; Ryan *et al.* 2007). From epidemiological significant, FMD in sheep and goat is considered as carriers of infection to other ruminants and wild animals (Ganter *et al.* 2001).

*Received Dec 25, 2018 \* Published Feb 2, 2019 \* www.ijset.net*

There are several reports suggesting vertical transmission of FMD virus causing abortion in sheep (Geering *et al.* 1976; Nazliglu, 1972). Abortion occurred at various stages of gestation and mostly noticed with 6 weeks from the onset of the outbreak (Ryan *et al.* 2007). Deaths in lambs begin two to three days after the beginning of clinical signs in the ewes, and are usually resulting from heart failure due to myocarditis, septicemia, abomasitis and enteritis (Littlejohn, 1970). The present article is just trying to prove that FMDV is one of the etiological agents causing abortion in indigenous sheep in Saudi Arabia.

## MATERIALS AND METHODS

### **Animals:**

A sheep farm was attacked with FMDV during summer 2017. The farm has not been vaccinated and there is a history of new entrance of animals. A total of 6 aborted lambs was submitted to the necropsy room at Department of Veterinary Pathology.

### **Post mortem examination and samples:**

A thorough postmortem examination was performed on dead lambs. Gross findings were described and recorded. Tissue samples from myocardium, liver, kidney, abomasum and intestine were preserved in 10% neutral formalin and are processed. Paraffin sections were stained with hematoxylin and eosin (HE). Oral swabs from freshly ruptured vesicles were collected and kept in 0.04 M phosphate buffer saline with 50% glycerol. Heart tissue samples were collected, then ground in 0.04 M phosphate buffer saline with 50% glycerol followed by three times of freezing and thawing. The supernatants were centrifuged at 5000 rpm for 10 min then stored at -80°C.

**RNA extraction:** Total RNA was extracted from sample supernatants using QIAamp Viral RNA Mini Kit (QIAGEN, USA).

**Molecular detection of FMDV:** The extracted RNAs were tested for the presence of FMDV using One-step RT-PCR Kit (QIAGEN, USA). The RT-PCR reaction mixture consisted of 5 µl of the total RNA, 5 µl 5x Qiagen one-step RT-PCR buffer, 5 µl Q buffer, 1 µl of dNTPs mix, 1 µl (50 pmol) of each forward primer; 5'-GCCTGGTCTTTCCAGGTCT-3' and Reverse primer; 5'-CCAGTCCCCTTCTCAGATC-3' (Reid *et al.* 2000).

## RESULT AND DISCUSSION

FMDV has a potential to become an emerging and bioterrorism agents because it has a major problem in animals and animal products. FMDV in sheep is milder than in cattle and pigs with viremia persists up to 3 days before the beginning of vesicles (Alexandersen *et al.* 2003). During summer 2017, an outbreak of FMDV attacked a sheep farm which has not

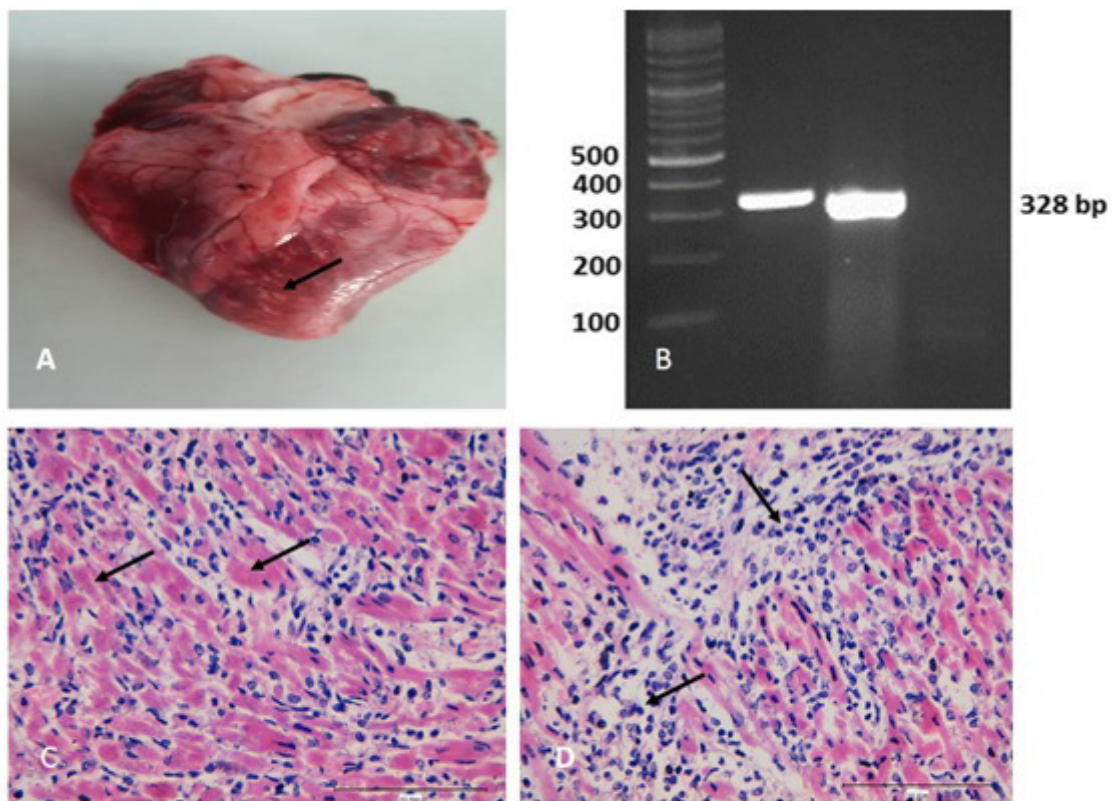
previously been vaccinated and has a history of new entrance of animals. Clinical signs were fever up to 42°C and nasal discharge. There was also excessive salivation and oral eruptions associated with erosions along with interdental spaces. This was accompanied by abortion in some pregnant ewes in the last trimester of pregnancy. These signs were confirmed as FMDV by detection of virus on oral swabs by using PCR techniques (Figure 1b). Furthermore, the lesions were quite similar to those observed previously in infected sheep and goat with FMDV (Brown, 2002; Reid, 2002). Myocarditis in ruminants caused by different microbial agents, viral, parasitic or bacterial organism (Smith, 2009). In this study, aborted lambs revealed necrotic foci in ventricular wall (Figure 1a) which diagnosed histologically as viral myocarditis due to the presence of large amounts of lymphocytes ((Figure 1c, d). This myocarditis was confirmed as FMDV by PCR technique (Figure 1b). Myocarditis without vesiculation has been recorded in young animals and cause high mortality in malignant foot and mouth disease (Barker *et al.* 2005). This finding was consistent with several reports among myocarditis in sheep, goat and calves (Ryan *et al.* 2007; Tunca *et al.* 2008; Karapinar *et al.* 2010; Hemanth *et al.* 2014). Vertical transmission of viral DNA and RNA has been recorded by several workers (Amedee *et al.* 1995; Zhang *et al.* 2005). There are early reports suggested vertical transmission of FMDV causing abortion in sheep (Geering, 1967; Nazliglu, 1972). This study clarified that FMDV in ewe can cross the placenta and lead to fetal death and abortion. In conclusion, FMDV could be considered as one of viral agents can cause abortion among indigenous sheep in Saudi Arabia.

## REFERENCES

- [1] Alexandersen, S., M. Quan, C. Murphy, J. Knight and Z. Zhang (2003). Studies of quantitative parameters of virus excretion and transmission in pigs and cattle experimentally infected with foot-and-mouth disease virus. *J Comp Pathol.* 129(4): 268–82.
- [2] Alexandersen, S., Z. Zhang, A.I. Donaldson and A.J.M. Garland (2003). The pathogenesis and diagnosis of foot and-mouth disease. *J Comp Pathol* 129:1-36 .
- [3] Amedee, A.M., N. Lacour, J.L. Gierman, L.N. Martin, J.E. Clements, R. Bohm, Jr., R.M. Harrison, and M. Murphey-Corb (1995). Genotypic selection of simian immunodeficiency virus in macaque infants infected transplacentally. *J. Virol.* 69:7982-7990 .
- [4] Barker, I.K., A.A. Van Dreumel and N. Palmer (2005). The alimentary system. In: *Pathology of Domestic Animals*, 4th ed. K.V.F. Jubb, P.C. Kennedy and N. Palmer Eds.). Academic Press, San Diego, pp.141-144 .

- [5] Belsham, G.J. (1993). Distinctive features of foot-and-mouth disease virus, a member of the picornavirus family; aspects of virus protein synthesis, protein processing and structure. *PBMB* 60:241-260 .
- [6] Brown, D.J. (2002). FMD in a parturient sheep flock. (Letter). *Vet Rec.* 151:127.
- [7] Charleston, B., B.M. Bankowski, S. Gubbins, M.E. Chase-Topping, D. Schley and R. Howey, et al. (2011). Relationship between clinical signs and transmission of an infectious disease and the implications for control. *Science* 332(6030):726–9 .
- [8] Ganter, M., W.D. Graunke, G. Steng and H. Worbes (2001). FMD in sheep and goats. *DTW* 108:499-503 .
- [9] Geering, W.A (1967). Foot-and-mouth disease in sheep. *Aust Vet J.* 43:485–9 .
- [10] Grubman, M.J. and B. Baxt (2004). Foot-and-mouth disease. *ClinMicrobiol Rev.* 17(2):465–93.
- [11] Hughes, G.J., V. Mioulet, R.P. Kitching, M.E. Woolhouse, S. Alexandersen and A.I. Donaldson (2002). Foot-and-mouth disease virus infection of sheep: implications for diagnosis and control. *Vet Rec.* 150:724-727 .
- [12] Hemanth, I., P. Amaravathi, N. Babu, A.Kumar, N. Sailaja (2014). Malignant form of foot and mouth disease outbreak in sheep and goat with reference to cytological and histopathological findings. *Indian J Vet Pathol.* 38(2):82-84 .
- [13] Karapinar, T., D.O. Dabak, T. Kuloglu and H. Bulut (2010). High cardiac troponin I plasma concentration in a calf with myocarditis. *Can Vet J.* 51:397-399.
- [14] Littlejohn, A. (1970). FMD in sheep - part 1. *SVJ* 25, 3-12, 1970.
- [15] Nazliglu, M (1972). Foot and mouth disease in sheep and goats. *Bull Off intEpiz.* 77:1281-4.
- [16] Orsel, K., A. Bouma, A. Dekker, J.A. Stegeman and M.C. de Jong (2009). Foot and mouth disease virus transmission during the incubation period of the disease in piglets, lambs, calves, and dairy cows. *Prev Vet Med.* 88(2):158–63.
- [17] Ryan, E., Z. Zhang, H.W. Brooks, J. Horsington and J. Brownlie (2007). Foot and Mouth disease virus crosses the placenta and causes death in fetal lambs. *J Comp Path.* 136:256-265 .
- [18] Reid, S., N.P. Ferris, G.H. Hutchings, A.R. Samuel and N.J. Knowles (2000). Primary diagnosis of foot-and-mouth disease by reverse transcription polymerase chain reaction. *J Virol Methods* 89:167–176 .
- [19] Reid, H.W. (2002). FMD in a parturient sheep flock. *Vet Rec.* 150:791.

- [20] Smith, B.P. (2009). Foot and mouth disease. In: Large Animal Internal Medicine. 4th ed. St. Louis, Missouri, Mosby, pp.802-903.
- [21] Stenfeldt, C., M. Eschbaumer, J.M. Pacheco, S.I. Rekant, L.L. Rodriguez and J. Arzt (2015). Pathogenesis of Primary Foot-and-Mouth Disease Virus Infection in the Nasopharynx of Vaccinated and Non-Vaccinated Cattle. PLOS ONE 10 .
- [22] Tunca R., M. Sozmen, H. Erdogan, M. Cital, E. Uzlu, H. Ozen and E. Gokce (2008). Determination of cardiac troponin I in the blood and heart of calves with foot-and-mouth disease. J Vet Diagn Invest. 20:598-605.
- [23] Zhang, S., A.L. McNees and J.S. Butel (2005). Quantification of vertical transmission of Murine polyoma virus by real time quantitative PCR. J Gen Virol. 86(Pt 10):2721-9.



**Fig.1. A.** Greyish white necrotic foci through myocardium (arrow). **B.** Agarose gel electrophoresis of RT-PCR amplified products of FMDV field samples. Lanes M, GeneRuler 100 bp Plus DNA Ladder (ThermoFisher Scientific); Lane 1, Vesicular fluid sample; Lane 2, Heart tissue sample and Lane 3, water served as negative control. **C.** Hyaline degeneration of myocardium muscles HE Bar=100 $\mu$ m. **D.** Infiltration of degenerated myocardial muscles with lymphocytes and macrophages HE Bar=100 $\mu$ m.