

SUCCESSFUL SURGICAL MANAGEMENT OF BILATERAL INGUINAL HERNIA IN INTACT MALE DOGS

K Lavanya¹, P Ravi Kumar^{2*} and Ch Mallikarjuna Rao²

¹Assistant Professor, Dept. of Veterinary Surgery and Radiology,
College of Veterinary Science, Garividi,

Sri Venkateswara Veterinary University, Tirupati

²Assistant Professor, Dept. of Veterinary Surgery and Radiology,
Veterinary Hospital, Vishakhapatnam,

Sri Venkateswara Veterinary University, Tirupati

E-mail: ravikumarvallitvm1018@gmail.com (**Corresponding Author*)

Abstract: Four intact male dogs of varied age groups, with a swelling on either side of the shaft of penis were diagnosed to have bilateral inguinal hernia. Clinical examination, radiography and ultrasonography aided in diagnosis. The hernial contents noticed were omentum in two cases; omentum and intestines in one case; and spleen and intestines in one case. Herniorrhaphy was performed to repair hernia in three cases; whereas, in one case hernioplasty was performed. No postoperative complications were recorded and all the animal recovered uneventfully. The findings of clinical examination, radiography and ultrasonography; and the treatment strategies adopted were discussed.

Keywords: Bubanocele, herniorrhaphy, hernioplasty, dogs.

Introduction

Protrusion of organs or tissues through the inguinal canal adjacent to vaginal process is termed as inguinal hernia or Bubanocele and it could be classified as congenital and acquired (Ravikumar and Ranganath, 2014). The clinical symptoms exhibited by the animal reflect the size of hernia, contents of hernia and its severity (Alireza et al, 2009). Radiography and ultrasonography aids in diagnosis of type of hernia and the hernial contents. Trauma is the common etiological factor for the development of inguinal hernia in adult dogs. In the present paper diagnosis and management of bilateral inguinal hernias in four intact males was described.

Case history and observations:

Four male dogs aged 2 years to 12 years were presented to the Veterinary Hospital, Vishakhapatnam, Sri Venkateswara Veterinary University, Tirupati with a complaint of swelling on either side of shaft of penis for the past few months. The abdominal rent with reducible contents could be palpated in one case; whereas, in the remaining cases the mass

found irreducible with no palpable rent, which later confirmed as hernia by the finding of radiography and ultrasonography.

S.No	Anamnesis	Radiography findings	Ultrasonography findings	Hernial contents	Type of hernia
Case-1	Pomeranian, Intact Male, 8 years. (Fig-1)	Tightly packed loops of intestines protruding out of the body wall. (Fig-5)	Tubular fluid filled structures with peristalsis.	Intestines and omentum	Reducible
Case-2	Non descriptive, Intact Male, 12 years. (Fig-2)	Radiopaque mass continuing into the body wall in both the hernias.	Mass of homogenous echogenicity and a break in continuity of body wall suggesting the presence of hernial ring (Fig-6)	omentum	Irreducible
Case-3	Non descriptive, Intact Male, 8 years. (Fig-3)	Radiopaque mass continuing into the body wall in both the hernias	Mass of homogenous echogenicity with fluid surrounding to it (Fig-7)	Omentum (Fig-8)	Irreducible
Case-4	Pomeranian, Intact Male, 2 years. (Fig-4)	The mass containing intestinal loops in left side hernia and spleen in right side hernia	A homogenous echogenic tissue continuing with spleen in left side hernia and tubular structures with peristalsis in right side hernia	Spleen (Left side) and intestines (Right side) (Fig-9 &10)	Irreducible

In case-1 the hernial rings appeared too large to repair by herniorrhaphy, hence mesh hernioplasty was planned in it; whereas, in the remaining cases herniorrhaphy was opted. The physiological activities had appeared normal in all the cases except in case-4 where the hernial contents are spleen and intestines. The same dog showed mild neutrophilia, anemia and elevated Creatinine levels.

Treatment

All the animals were stabilized with administration of intravenous crystalloids, antibiotics and alterative drugs on the day of their presentation and the surgery was deferred to later date until the animals get stabilized. After aseptic surgical preparation, the dogs were given

subcutaneous injection of Atropine sulphate @0.04mg/Kg body weight as a Preanesthetic drug and intravenous injection Ketamine Hcl @ 5mg/Kg body weight along with injection Diazepam @ 0.5mg/Kg body weight for induction of anesthesia. The anesthesia was maintained with Isoflurane inhalant anesthesia. Herniotomy was performed on either side in all the cases and attempts were made to reduce the contents. Kelotomy was performed in case 2, 3 and 4 where the contents were irreducible; whereas, in case-1 the contents got reduced easily as the size of hernial ring is large. Inlay mesh hernioplasty (Fig-11) was performed with nylon mesh in case 1 and the skin edges were apposed as per standard procedure. In the remaining cases after reduction of the contents the hernial ring was closed by application of vest over pant sutures using Vicryl No-1 (Polyglactin 910). The skin edges were apposed by cross mattress sutures using nylon in two cases (Fig-12) and by simple interrupted sutures using silk no 2-0 in two cases (Fig-13). Postoperatively, all the animals were given injection ceftriaxone sodium @ 25mg/Kg body weight for 5 days, Meloxicam @ 0.2mg/Kg body weight for 3 days, normal saline @40ml/Kg body weight and supportive therapy with antioxidants tablets and multivitamin tonics orally for 15 days. Uneventful recovery was observed in all the cases except in case 2 where scrotal edema (Fig-14) was noticed on tenth postoperative day which was later resolved by giving treatment.

Discussion

In the present study, the inguinal hernia was noticed in four adult and intact male dogs. Waters et al, (1993), opined that acquired inguinal hernias are common in middle aged intact bitches; whereas in the present study the cases were reported in intact male dogs. In the present study the type of hernias are bilateral and reported in adult animals. The present findings differ with the opinion made by Bellenger, (1996), who opined that bilateral hernias more frequently seen in young dogs. Several theories were proposed to explain the etiological factors responsible for the development of inguinal hernia in female dogs such as anatomical factors (Smeak, 1993a), hormonal (Hayes, 1974) and metabolic factors (Smeak, 1993b). In the present study, the etiology is unknown in all the cases. Diagnosis of the condition was done with the help of physical examination, radiography and ultrasonography. Abdin and Ramadan, (2001) opined that, diagnosis of inguinal hernia could be achieved with the help of radiography and ultrasonography in dogs. In the present study in addition to omentum, intestines and spleen were also noticed as hernial contents which deviates the statement given by Fossum et al., (2002) who reported that, omentum could be seen as a common hernial content in inguinal hernia as the hernial ring was small. Herniation of spleen which was

observed in case-4 could be considered as a rare finding as, there were no, or very less reports mentioning it in dogs. Herniorrhaphy was performed in all the cases except in case-1, where inlay mesh hernioplasty was performed to close the large hernial ring. Alireza et al, (2009) mentioned that, complications like infection at the site of incision, wound dehiscence, seroma, hematoma, recurrence of hernia, sepsis and death may occur followed by hernial repair. No such complications were reported in the present study and all the animals recovered uneventfully.

References

- [1] Abdin-Bey, M.R and Ramadan, R.O (2001): Retrospective Study of Hernias in Goats. Scientific Journal of King Faisal University (Basic and Applied Sciences), 2(1):77-8.1
- [2] Alireza R.J, Seifollah D.N, Musa J.G, and Samira M. (2009): Concurrent bilateral inguinal and umbilical hernia in a bitch: case report, Veterinarski Archive 79 (5): 517-522.
- [3] Bellengar C.R, (1996): Inguinal and scrotal herniation in 61 dogs. Australian veterinary practice 26:58.
- [4] Fossum, T.W., S.H. Choyl, A.H. Doland, L.J. Ann, B.S. Howard, D.W. Michael (2002): Small Animal Surgery. 2nd Ed., Mosby Inc Missouri. pp. 261-267.
- [5] Hayes H.M. (1974): Congenital umbilical and inguinal hernia in cattle, horse, swine, dogs and cats: risk by breed and sex among hospital patients. American journal of veterinary research, 35:839-842.
- [6] Ravikumar S and Ranaganath L (2014) Surgical management of inguinal hernia in a male dog. Indian journal of canine practice, 6(1):53-55.
- [7] Smeak D.D. (1993a): Abdominal hernias. In: Slatter D, ed. Textbook of Small Animal Surgery, 2nd ed. vol 1. Philadelphia: WB Saunders, 433-454.-511.
- [8] Smeak D.D. (1993b): Abdominal hernias. In: Bojrab MJ, ed. Disease Mechanisms in Small Animal Surgery. Philadelphia: Lea & Febiger, 98-102.
- [9] Waters D.J, Roy R.G, and Stone E.A. (1993): Retrospective study of inguinal hernia in 35 dogs. Veterinary surgery 22:44-49.







	
<p>Fig-1: Photograph showing hernia on either side of shaft of penis in case-1</p>	<p>Fig-2: Photograph showing hernia on either side of shaft of penis in case-2</p>
	
<p>Fig-3: Photograph showing hernia on either side of shaft of penis in case-3</p>	<p>Fig-4: Photograph showing hernia on either side of shaft of penis in case-4</p>
	
<p>Fig-5: Skiagram showing loops of intestines in the hernial sac.</p>	<p>Fig-6: Ultrasonogram showing the hernial ring in case-2</p>

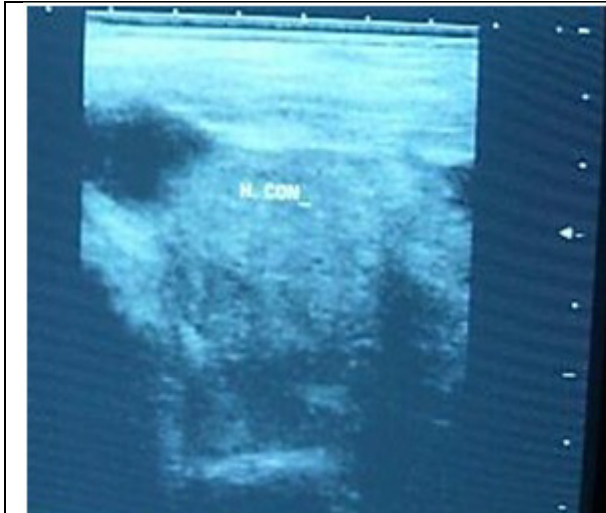

Fig-7: Ultrasonogram showing the mass of homogenous echogenicity with fluid surrounding to it in case-3

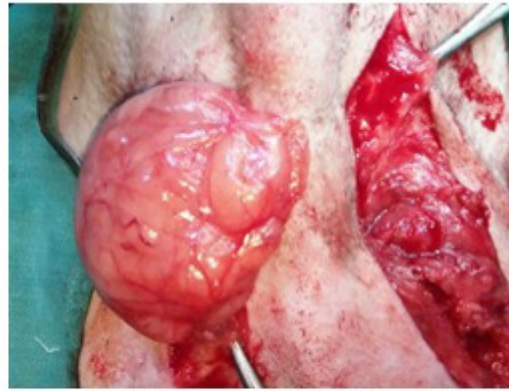

Fig-8: Intraoperative photograph showing omentum in the hernial sacs on either side of shaft of penis in case-2

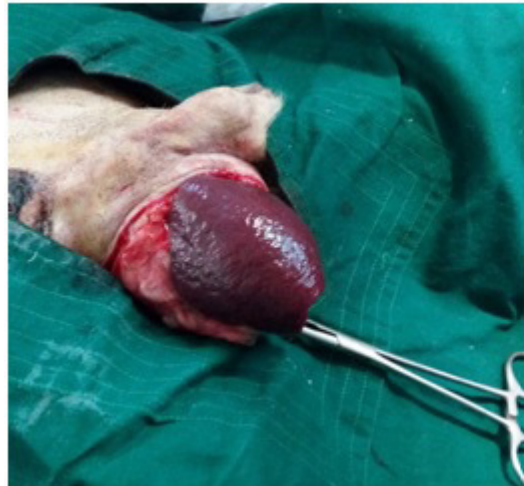

Fig-9: Intraoperative photograph showing spleen in the left inguinal hernia in case-4

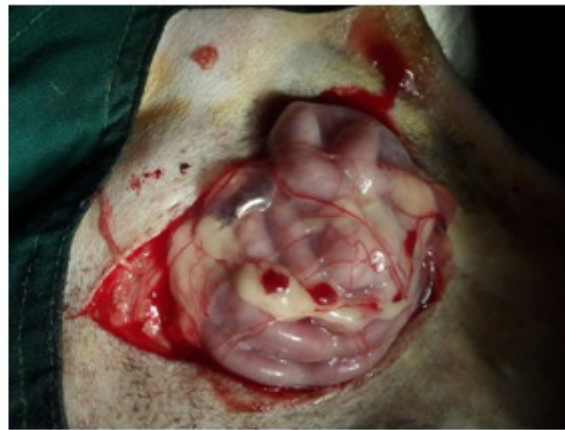

Fig-10: Intraoperative photograph showing spleen in the right inguinal hernia in case-4

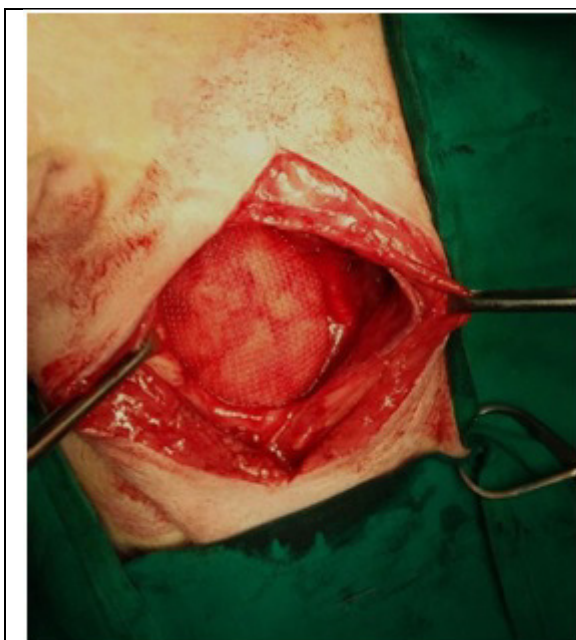


Fig-11: Intraoperative photograph showing the application of inlay mesh graft to repair the hernial ring in case-1

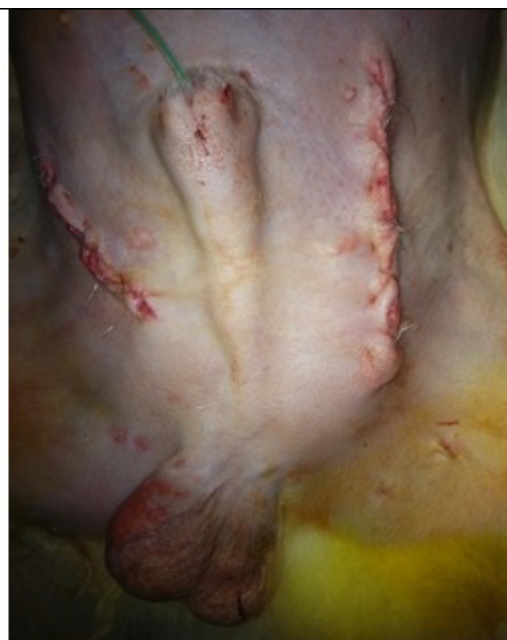

Fig-12: Immediate postoperative photograph showing the repair of bilateral hernial rings in case-2

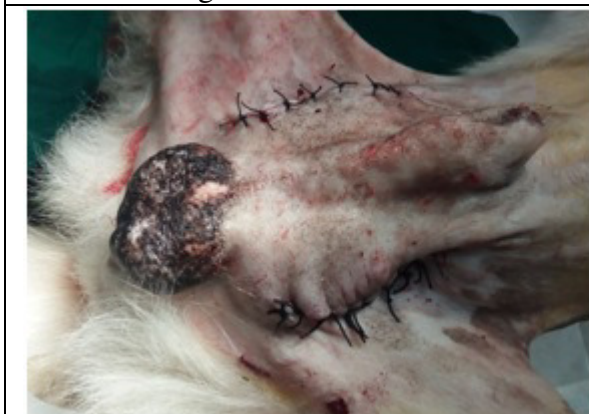

Fig-13: Immediate postoperative photograph showing the repair of bilateral hernial rings in case-4

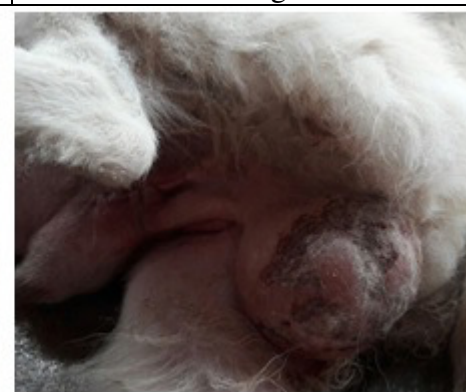

Fig-14: Photograph showing scrotal edema in case-2 on tenth postoperative day.