

HISTOCHEMISTRY OF UTERUS IN OSMANABADI GOAT DURING VARIOUS STAGES OF ESTROUS CYCLE

Bagade P.S., Mugale R.R., Thakur P.N. and Kapadnis P.J.

Department of Veterinary Anatomy,
College of Veterinary and Animal Sciences, Udgir [M.S.]

Abstract: PAS positive activity for glycogen appeared moderate in proestrous and metestrous phase while the activity was intense in estrous and became moderate to intense in diestrous phase. Further, the reaction to acid mucopolysaccharides was intense in estrous phase and it was comparatively reduced in other phases of estrous cycle.

Keywords: Histochemistry, Uterus, Osmanabadi goats, stages of estrous cycle.

INTRODUCTION

Goat was perhaps the very first animal species domesticated by man. The cyclical changes in the female genitalia offers basis for the diagnosis and investigation of functional disturbances leading to sterility and infertility. There is very close relationship between fertility and functions of genital organs and hormonal statuses and histochemical changes of reproductive organs.

Considering the importance of uterus in reproduction, the present study is undertaken to study the histochemistry of uterus in Osmanabadi goat.

MATERIAL AND METHODS

The study was conducted on 24 healthy Osmanabadi goats at different stages of estrous cycle. For the present study, the genitalias were brought to the laboratory of the department of Anatomy in ice pack thermos for the further study. The tissue pieces of 3-5mm thickness were cut from different parts of uterus and preserved in 10% neutral buffered formaline.

The tissue preserved in 10% neutral buffered formaline were then processed for routine paraffin embedding method and were cut at 3-5 μ thickness.[Singh and Sulochana, 1978]. For sectioning, manually operating rotary microtome was used. Following methods were used for the Histochemistry- McManus Periodic Acid Schiff [PAS] reaction stain for carbohydrate like glycogen, Reticulum and mucin [Mukherjee, 1990]. Mowry's Colloidal Iron stain for demonstration of Mucopolysaccharides [Singh and Sulochana, 1978].

RESULT AND DISCUSSION

For the demonstration of glycogen, Periodic Acid Schiff's [PAS] reaction observed for different components of uterus during various phase of estrous cycle. In the present study, the endometrium of uterus in proestrous showed moderate PAS positive reaction in the epithelial border, lamina propria, uterine glands, glandular epithelium along with myometrium and perimetrium. [Plate-1]

In estrous phase, PAS positive reaction was intense and it was observed as moderate to strong in endometrial epithelium, endometrial stoma, glandular epithelium, myometrium and perimetrium [Plate-2]. Intense PAS activity was observed during estrous. Similar observations were recorded by Larson *et al.* [1965] in bovine.

In metestrous phase, the PAS positive activity was moderately shown by endometrial epithelium, glandular epithelium, and myometrium [Plate-3].

In diestrous phase, the intensity of PAS positive activity was moderate to strong in epithelium of uterine glands. Similar observations were recorded by Leontidis [1968] in cow and Banubakode [2002] in goats. During various phases of estrous cycle, there was no PAS positive material in the lumen of uterus. This observation is in agreement with the findings recorded by Joshi *et al.* [1983]^b in goat. The moderate PAS activity was noted in the basement membrane of surface epithelium and uterine gland during estrous and diestrous phase while it was weak to moderate during metestrous.

Maximum PAS activity was observed in estrous phase [Plate-2]. The present observations are in agreement with Larson *et al* [1970] in bovine, moderate to strong PAS positive activity was observed in the glandular epithelium and basement membrane. No appreciable cyclical variations in the PAS activity could be noticed, Similar were the observations of Bhattacharya and Saigal [1984]^b in goat.

During proliferative phases there was a continuous increase in the amount of glycogen and mucin within the cells of the uterine glands. With the onset of secretory stage, both the glycogen and mucinogen increased rapidly in the gland cells. The observations are similar with the observations recorded by Foster [1960] and Copenhaver *et al.* [1978] in human. Glycogen was accumulated in uterus more in follicular phase than in luteal phase. These observations are similar with the observations made by Dwivedi and Singh [1972] in Indian buffalo.

Moderate to intense PAS activity was observed in the apical portion of epithelial cells and glandular epithelium. Glycogen content of uterine surface and glandular epithelial cells may

provide energy for the free-floating blastocyst and also for endometrial cell function. Similar observations were recorded by Wordinger *et al.* [1971] in bovine. Mild PAS activity in serosa and moderate to intense activity in blood vessels was observed during all the phases of estrous cycle. Similar observations were made by Dhale [2001] in goat.

In present study, the Mowry's colloidal iron activity was observed for acid mucopolysaccharides in different components of uterus during different phases of estrous cycle.

In uterus, the activity was found intense in uterine epithelium, uterine stroma, uterine glands, lamina propria and muscularis externa in estrous phase [Plate-4]. The activity was moderate to intense in other phases of estrous cycle revealed moderate to intense activity in uterine epithelium, uterine stroma, glands, myometrium and lamina propria. [Plate-3] The intense colloidal iron activity was recorded during estrous phase while in other phases this activity was comparatively reduced. Presence of mucopolysaccharides in epithelium during ovulation provides optimum conditions for spermatozoa. Similar observations were recorded by Horvath and Kiszely [1959] and Leontidis [1968] in cow and Banubakode [2002] in goats during various phases of estrous cycle.

LITERATURE CITED

- [1] Banubakode S.B. [2002]: Histological, histochemical and immunohistological changes in Oviduct & uterus during different phases of estrus cycle and early pregnancy in goat Ph.D. thesis submitted to MAFSU, Nagpur
- [2] Leontidis, S.L. [1968]: Histological and histochemical investigation of the bovine endometrium. The salaniki 9: 473 [Cited from Vet. Bull. 1970. 42: Abst. 1412].
- [3] Horvath, I. And G. Kiszely [1959]: Histochemistry of bovine endometrium [1] changes during estrus cycle. Acta Vet. Acad. Sc. Hung. 9: 27, 37 [Cited from Vet. Bull. 1960,30: Abst.892.].
- [4] Dhale, S.N. [2001] Histology and Histochemistry of uterus in goat. A dissertation Submitted to Marathwada Krishi Vidyapeeth, Parbhani for M.V.Sc. degree.
- [5] Wordinger, R.J.; J.F. Diskey and J.R. Hill [1971]: Histological and histochemical changes in bovine endometrium following treatment with a progestin. J. Dairy Sc. 54 [12]: 1872-1875.
- [6] Dwivedi, J.N. and C.M. Singh [1972]. Histochemical observation on the endometrium of Indian Buffalo Ind. J. Animl Health: 31-34.
- [7] Copenhagen, Wilfred M: Douglas E. Kelly and Richard L. Wood [1978] Baily's Textbook of Histology XVII Edition. PP 659-692. The Williams and Wilkins Company, Baltimore.

[8] Foster, C.L. [1960]: Hewers Textbook of Histology for Medical Students. PP 328-342. William Heinemann Medical Books Ltd.

[9] Bhattacharya, M. and R.P. Saigal [1984]^b: Histomorphological and histochemical studies on the uterus of goat [*Capra hircus*] during the reproductive cycle. Ind. J. Anim Sc. **54** [7]: 645-649.

[10] Larson, L.L.; G.B. Marion and H.T. Gier [1970] Glycogen metabolism in bovine endometrium. Am. J. Vet. Res. **31** [11]: 1929-1935.

[11] Joshi, C.L.; B.S. Nanda and R.P. Saigal [1983]^b: Histochemical observations on carbohydrates in the uterine wall of goat. J. Res. Punjab Agril. University. **20** [4]: 550-552.

[12] Leontidis, S.L. [1968]: Histological and histochemical investigation of the bovine endometrium. The salaniki 9: 473 [Cited from Vet. Bull. 1970. **42**: Abst. 1412].

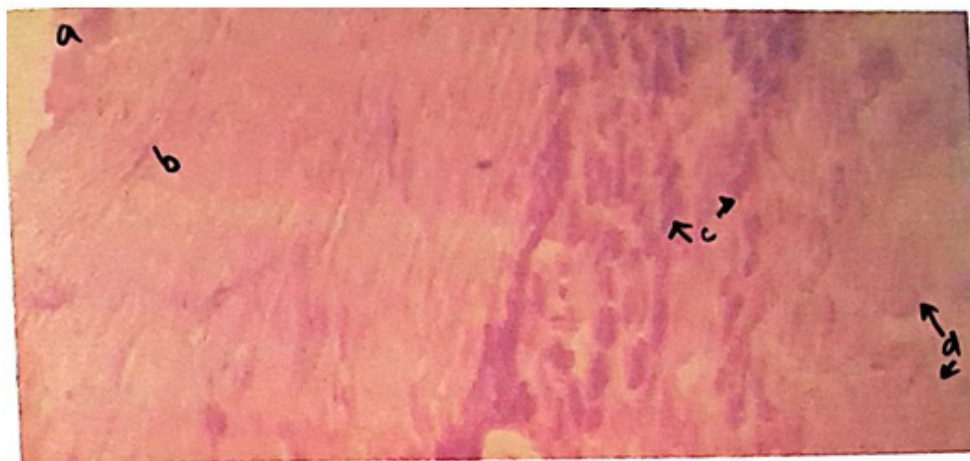


Plate No. 1 Microphotograph of Uterus during proestrous phase showing [PAS 10X]
a. Perimetrium b. Myometrium C. Endometrial Glands d. Mucosal folds

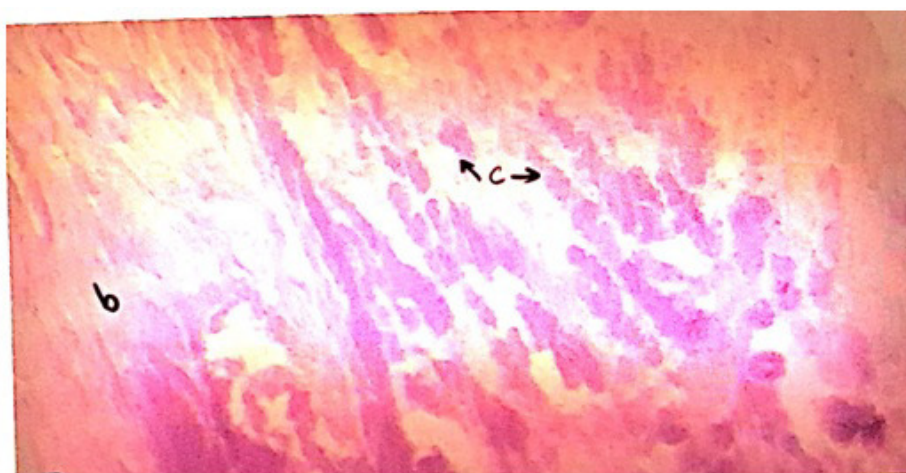

Plate No. 2 Microphotograph of Uterus during estrous phase showing [PAS 10X]
a. Perimetrium b. Myometrium C. Endometrial Glands



Plate No. 3 Microphotograph of Uterus during proestrous phase showing
[Morwreys Collidal iron 10X]

- a. Myometrium Circular b. Endometrial Glands c. Mucosal Folds

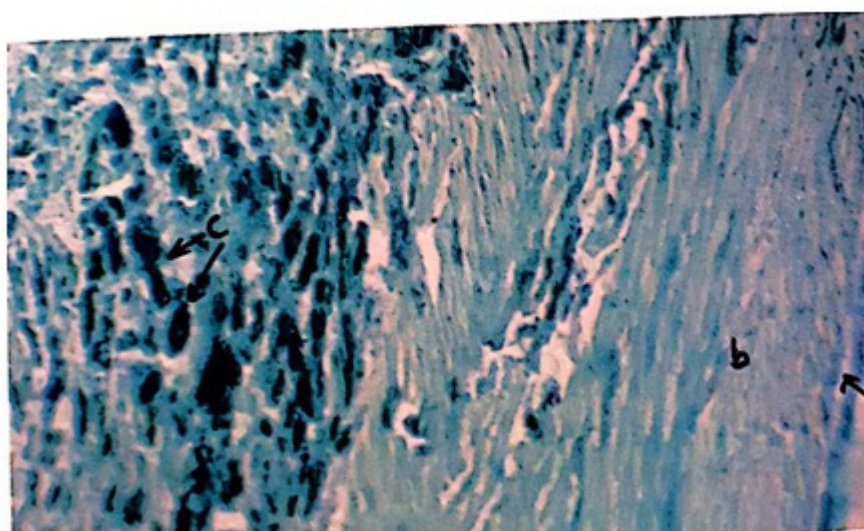


Plate No. 4 Microphotograph of Uterus during estrous phase showing
[Morwreys Collidal iron 10X]

- a. Perimetrium b. Myometrium c. Endometrial glands