

DYSTOCIA DUE TO MONOCEPHALIC THORACOPAGUS TETRABRACHIUS TETRAPUS MONSTER IN NAGPURI BUFFALO - A RARE CASE

B.M. Gahlod¹, S.B. Akhare², S.K. Sheetal^{3*} and M.S. Dhakate⁴

¹Hospital Registrar, ²Associate Professor, ^{3*}Hospital Registrar, & Corresponding author,
⁴Hospital Superintendent

Department of Teaching Veterinary Clinical Complex,
Nagpur Veterinary College, Nagpur (M.S.)

E-mail: ¹drbhushansingh@gmail.com ²sandeepakhare@yahoo.co.in ³sksheetalmuz@gmail.com

Abstract: A conjoint monster was delivered by caesarean section in a Nagpuri buffalo. Partially duplicated with single head (Monocephalic), two male fetuses joined at the thoracic region (Thoracopagus) and having well developed eight limbs, i.e. four forelimbs (Tetrabrachius) and four hind limbs (Tetrapus) and both pelvis are separate (Dicaudatus). A rare case of monocephalic thoracopagus tetrabrachius tetrapus monster in a Nagpuri Buffalo was reported with successful caesarean section operation with uneventful recovery.

Keywords: Conjoined twin, monster, thoracopagus, tetrabrachius, tetrapus.

Introduction

Monsters are the outcome of developmental disturbances that involves various organs and systems which can cause great distortion of the individual (Vegad, 2007). Abnormal duplication and/or disruption of the inner cell mass in an embryo give rise to congenital foetal abnormalities with partial duplication of body structures. Conjoined twins are also known as diplopagus monsters or Siamese twins. Structural or numerical duplication during the embryonic stage give rise to fetuses whose body structures are partially but not completely duplicated (Roberts, 1971). They are the result of incomplete division of a fertilized ovum and show great variation from partial duplication to almost complete separation of two individuals, joined in just a few places.

Duplication of cranial portion of foetus is more common than that of caudal portion (Roberts, 2004). It is important to know various types of monsters in animals that usually cause dystocia, which cannot be easily delivered and require a caesarean section or a fetotomy.

The incidence of foetal monsters, though rare, was reported by Sharma *et al.*, 2010; Singh *et al.*, 2011; Prasad *et al.*, 2012; Singh and Pandey, 2013; Sachan *et al.*, 2016 in buffaloes and Khasatiyan *et al.*, 2009; Jerome *et al.*, 2010; Ravikumar *et al.*, 2012; Sharma *et al.*, 2013; Kumar *et al.*, 2014 in cows. Dystokia is a common sequel of monstrosity and most of the

cases resolved by caesarean section. This communication reports a rare case of conjoined twin monster (Monocephalus Thoracopagus Tetrabrachius Tetrapus Dicaudatus) in a Nagpuri buffalo which was relieved by caesarean section.

Case History and Clinical Observations

A seven year old Nagpuri buffalo presented to Teaching Veterinary Clinical complex, Nagpur Veterinary College, Nagpur in recumbent condition with history of full term gestation and straining since last 24 hours, water bag ruptured 12 hr before and also the unsuccessful attempt was made by local paraveterinarian to relieve the dystocia. The animal was lethargic, dull, depressed. Detailed Gynaeco-clinical examination revealed that the birth canal was completely impacted with four limbs and pelvic cavity.

Per vaginal examination revealed no demarcation of thorax and many limbs were palpated at untoward places which confirmed the foetal monstrosity and might be prime cause for dystocia.

Treatment and Discussion

Forced extraction of monster was impossible due to completely impacted birth canal with four limbs and pelvic cavity of foetus, so it was decided to go for caesarean section to relieve the dystokia. The buffalo was stabilize with fluid therapy comprises of inj. Dextrose Normal Saline and Normal Saline 5 liter each, Ca-borogluconate 450 ml and antibiotic, antihistaminic and antiinflammatory were administered. Caesarean section was performed by lower left flank and a full term dead male monster was removed. The animal was able to stand after 6 hours without assistance and walks for dew steps. After 24 hour animal showed clear signs of improvement with improved appetite. The antibiotics, antihistaminic and antiinflammatory along with intravenous fluids were administered for 5 post operative days. The skin sutures were removed after 12th day of caesarean section and animal recovered uneventfully.

The monster was a conjoined male twin with fused at the thoracic region containing two pairs of fore limbs and posterior regions of both twins were well developed and having separate pelvis with external genitalia and rectum and pair of hind limbs. They have also two separate tails (dicaudatus). There was single head and neck, two eyes, having two ears, two clear nostrils with complete jaws (Figure – 1 & 2).

Conjoined twins may be caused by number of factors such as genetic, environmental, and infectious agents. Assisted reproductive techniques such as In vitro fertilization (IVF) and Intra cytoplasmic sperm injection (ICSI) may be a factor (Romero *et al.*, 1988). The embryonic disk starts to differentiate on the 13th day of conception. If the split occurs after

day 13, then the twins will share body parts in addition to sharing their chorion and amnion (Finberg, 1994). This type of foetus is due to congenital embryonic duplication of germinal layer arising from single ovum (Kumar and Reddy, 2008) that gives rise to monozygotic foetus with partial duplication of body structures. Simon *et al.*, (2009) stated that conjoined twins were always genetically identical and shared the same sex. The present case seemed to be a non-inherited teratogenic defect of development as there was no history of monstrosity in previous calving.

Radiographic Findings

The head and neck region was formed in the larger foetus only. The smaller foetus was attached to the larger one at the cranial end of its abdominal cavity behind the left forelimb. Both foetuses had two fully formed forelimbs and two hind limbs each. Radiographically, two different skeletons were visible in the monster in its thoraco-lumbar lateral and oblique ventro-dorsal radiographic projections. The primary larger foetus had properly developed forelimbs, a thoraco-lumbar spine as well as hind limbs (Figure – 3).

The smaller foetus showed fully developed forelimbs composed of a scapula, humerus, radius, ulna and distal bones. The thoraco-lumbar spine was evident but was not very clear as all the vertebrae were apparently smaller, compressed and distorted in shape. However, eight ribs were identifiable which converged at its spine which was found to be attached at a relatively ventral aspect of the thorax of the larger foetus (Figure – 4).

There were comparably fully developed pelvic bones which were attached with the spine almost at the area from where the forelimbs originated. However, the correctness of the configuration of the pelvic girdle in the smaller foetus could not be ascertained due to the lack of a sufficient number of radiographic images.

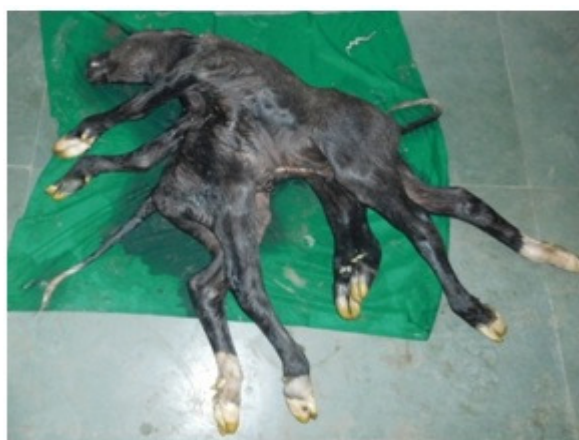

Figure 1: Full developed conjoined twin with eight limbs

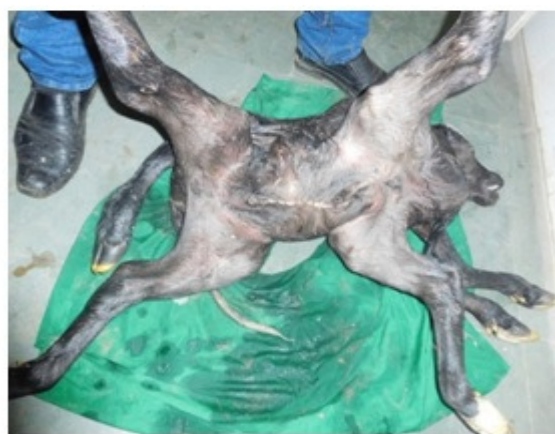

Figure 2: Conjoined male twin fused at the thoracic region

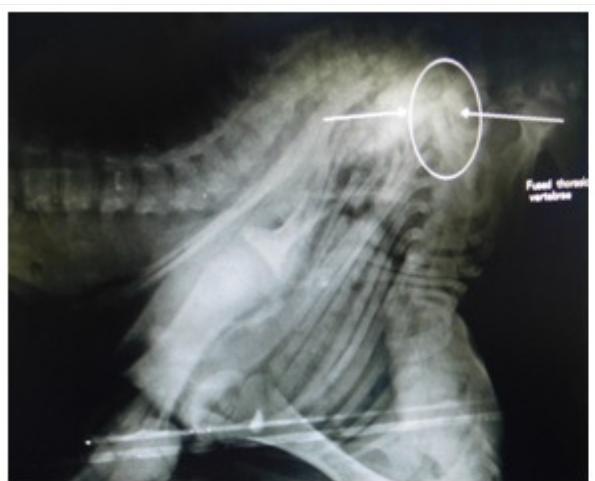


Figure – 3 Fused thoracic vertebrae

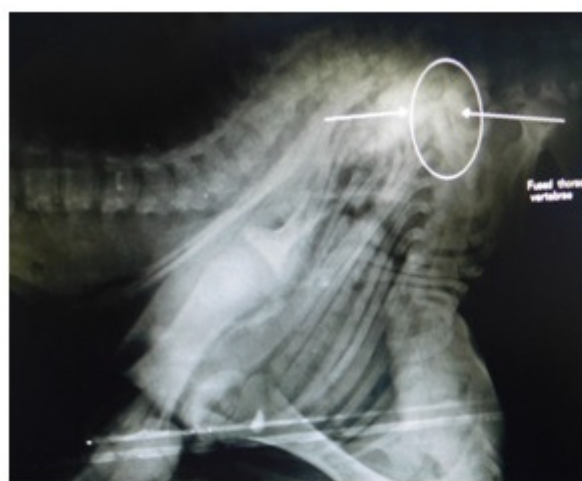

Figure – 4 Attached spine with the thorax of large foetus

References

- [1] Finberg, H.J. (1994). Ultrasound evaluation in multiple gestations, p. 121-124. In Callen's Ultrasonography in Obstetrics and Gynecology, 3rd ed. Harcourt Publishers.
- [2] Jerome, A., T. Sarath and N. Arunmozhi. (2010). Dystokia due to a conjoined twin monster in a buffalo. *Buffalo Bull.*, 29: 229-231.
- [3] Khasatiya, C.T., D.M. Patel, D.M. Dabhi and P.P. Choudhary. (2009). Dystokia due to dicephalus dipagus monster in a dangi cow. *Indian J. Anim. Reprod.*, 29: 224-225.
- [4] Kumar, S., Pandey, A. K., Kushwaha, R. B., Sharma, U. and Dwivedi, D. K. (2014). Dystokia due to conjoined twin monster in a cow. *Indian J. Anim. Reprod.*, 35(1): 54-56.
- [5] Kumar, Y.N. and A.R.M. Reddy. (2008). Syncephalus Buffalo Bulletin (March 2016) Vol.35 No.1 26 dipus tetrabrachius tetrapus dibrachius monster in ewe. *Indian Vet. J.*, 85: 1335.
- [6] Prasad, J.K., Das, G.K., Krishnappa, B., Kumar, B., Ramteke, Rakesh, S. H.B., Singh, M., Sharma, G.C. and Soni, Y. (2012). Monocephalic tetrabrachius tetrapus monster in amurrah buffalo. *Indian J. Anim. Reprod.*, 33(1): 96-97.
- [7] Ravikumar, K., M. Selvaraju and S. Manoharan. (2012). Dystokia Due to "Dicephalus Tetrabrachius Thoracopagus Tetrapus Dicaudatus" monster in a Jersey crossbred cow. *Indian Vet. J.*, 89: 96-98.
- [8] Robert, S.J. (1971). *Veterinary Obstetrics and Genital Diseases*, 2nd Indian ed. CBS Publishers, New Delhi, India.
- [9] Roberts, S.J. (2004). *Veterinary Obstetrics and Genital Diseases*. CBS Publishers, New Delhi, India.

- [10] Romero, R., G. Pilu and P. Jeanty (1988). Prenatal Diagnosis of Congenital Anomalies. Norwalk, CT, Appleton and Lange. p. 405- 409.
- [11] Sharma, A., Kumar, P., Singh, M., Vasishta, N.K. and Jaswal, R. (2013). Rare foetal monster in Holstein crossbred cow. *Open Veterinary Journal*, 3(1): 8-10.
- [12] Sharma, A., S. Sharma and N.K. Vasishta. (2010). Diprosopus buffalo neonate: A Case report. *Buffalo Bull.*, 29: 62-64.
- [13] Simon, M.S., B.J. William and T.A. Kannan (2009). A rare case of conjoined twin monster (Ischiopagus) in a she buffalo. *Indian J. Anim. Reprod.*, 30: 90-91.
- [14] Singh, G., Pandey, A.K., Agnihotri, D., Sunder, S., Kumar, S., Kumar, R., Dutt, R. and Singh, K. (2011). A case of rare monstrosity in a cow calf. *Haryana Vet.* 50: 101.
- [15] Singh, G. and Pandey A.K. (2013). Dystokia due to conjoined twin monsters in murreh buffaloes. *Haryana Vet.* 52:139-140.
- [16] Vegad, J.L. (2007). Textbook of Veterinary General Pathology, 2nd ed. International book distribution Company Lucknow, U.P., India.