

## HISTOMORPHOLOGICAL STUDIES ON INTESTINAL LYMPHOID TISSUES IN KADAKNATH BREED OF POULTRY (*Gallus gallus domesticus*)

Dr. Prashant Gedam<sup>1</sup>, Dr. Amol Salankar<sup>2</sup>, Dr. U.P. Mainde<sup>3</sup>, Dr. Naresh Nandeshwar<sup>4</sup>,  
Dr. Rasmita Panda<sup>5</sup>, Dr. T. Rama<sup>6</sup>, Dr. V. Ravikanth<sup>7</sup>, Dr. Sandip Shahapure<sup>8</sup>

<sup>1,2,3,4</sup>Nagpur Veterinary College, Maharashtra, Nagpur

<sup>5,6,7,8</sup>College of Veterinary Science, Korutla

E-mail: nvc1828@rediffmail.com

**Abstract:** The samples were divided into three age group viz. GI (6 weeks), GII (12 weeks) and GIII (18 weeks). The duodenum and jejunum showed no much remarkable differences. The villi were long and slender in duodenum and jejunum. Their tips were more slender in ileum with thicker base. The diffuse lymphatic tissues was scattered in the lamina propria, submucosa in all parts of small intestine. At few places the solitary lymphatic nodules were observed. The amount of lymphatics was more in Gr. II (12 weeks). The caeco-colic junction showed the aggregation of lymphatic nodules which were predominant in 12 week old birds. These were referred as the caecal tonsils which correspond to mammalian Peyer's patches. These nodules were covered with epithelium, forming dome and were devoid of goblet cells. The colon showed the diffuse lymphatic tissue in all the three age groups of the present study, but major infiltrations occurred in G.II and Gr. III. The goblet cells were numerous and intraepithelial lymphocytes were not recorded in colon.

**Keywords:** Kadaknath, lymphoid tissue, ceecal tonsils, poultry, intestine.

### 1. Introduction

Introduction: The Indian poultry industry has undergone a paradigm shift in structure and operation from merely a backyard venture into a major commercial and most progressive activity in a very short time. India is ranking currently fifth in the world as a broiler producer and fourth in the egg production. The annual egg production in India is recorded as 53,000 million and poultry meat as 3.2 million tones. (Saxena, 2009).

Kadaknath breed of poultry is reared since long time by tribals of Bhil and Bhilala community of Jhabua and Dhar districts of Western Madhya Pradesh. The black coloration of the flesh is due to the deposition of melanin pigment in the connective tissue of organs and in the dermis (Rao and Thomas, 1984). The bird is resistant to extreme climate conditions and is well adapted to the local environment. This breed is resistance to the diseases as compared to the exotic breeds even in adverse conditions like poor housing and management.

**Significance:** The avian alimentary tract is a common entry point for many potentially harmful pathogens. A wide range of factors associated with diets and infectious disease agents can negatively affect the delicate balance among the components of the chicken gut and as a result, affect health status and production performance of birds in commercial poultry operations (Yegani and Korver, 2008). The lymphoid tissue of the gut has a significant role in preventing diseases caused by gut pathogens (Hanger and Heath, 1994). It is possible that this tissue respond to antigen, gaining access via the mucous membrane. Hence it is essential to classify the fundamental structure in order to probe the immune mechanism of the gastrointestinal tract.

## **2. Materials and methods**

The present research work was carried out on histomorphological and histochemical studies on intestinal lymphoid tissue in 30 birds of Kadaknath breed of poultry. The samples were divided into three age group viz. GI (6 weeks), GII (12 weeks) and GIII (18 weeks). The general histomorphological observations were made from the sections stained with Haematoxylin and Eosin. The special stains were employed to study the presence of connective tissue, i.e. Masson's Trichrome to differentiate the collagen and muscle fibers, Gomori's stain for reticular fibers and Verhoeff's stain for elastic fibers.

## **3. Result and discussion**

### **1. Duodenum**

The mucosa was made up of epithelium, lamina propria and muscularis mucosa. The duodenal villi were long, slender and lined by simple columnar epithelium with many goblet cells. The lamina propria was made up of loose connective tissue and was infiltrated with diffuse lymphatic tissue (Fig.1). The other cells like lymphoblast, plasma cells, macrophages and erythrocytes were also noted in the lamina propria. Some solitary lymphatic nodules were also occurred in the duodenum in all age groups (Fig .2). The nodules were present in non villus area. The frame work of the villus was made up of reticular fibers and few elastic fibers. Few smooth muscle fibers were also observed to be extended up to the tip of villus. The intraepithelial lymphocytes (IEL) were found in the epithelium. The IEL were occurred as individual cells as well as in the form of small clusters. The epithelial lining was disrupted because of the number of clusters of IEL (Fig 1).

### **2. Jejunum**

In jejunum the lamina propria was blended with muscularis externa (Fig. 3). There was no distinction between mucosa and submucosa. Histologically there was no any

remarkable difference occurred between duodenum and jejunum in different group of animals. There was heavy infiltration of diffused lymphatic tissue in Gr.II & III. (Fig.3). Besides the lymphocytes, other cells like plasma cells, lymphoblasts, eosinophils, erythrocytes were also found, but the lymphocytes were predominant. The IEL were present individually and also in the form of clusters in all age group .

### 3. Ileum

The villi were long but broader at the base and their tips were more slender. The lymphocytes were highly concentrated in lamina propria and were loosely scattered in subepithelium and also in the epithelium (Fig.4). The lamina propria showed the intricate network of the reticular fibers. Some elastic and collagen fibers were also occurred. The connective tissue fibers were course in Gr.III. The sub mucosa was absent and the lamina propria and muscularis mucosae were blended with muscularis externa. The IEL were found in all groups. They were observed to be reduced towards the terminal part of ileum, and were replaced by many goblet cells. The intestinal glands were numerous. The observation recorded in the small intestine of present study was in accordance with the Kalitha et. al (2010) in Kadaknath fowl. The diffuse lymphatic tissues as well as lymphatic nodules occurred in all parts of small intestine and in all the three groups indicate that there exists a mucosal immune system in chicken besides the primary lymphatic organs. The birds used for the present study were up to the age of 18 weeks and in all the birds the infiltration of the lymphatic tissues was observed. Befus et. al (1986) observed that the number of the nodules decreased as the age advanced. The heavy infiltration showed up to 16 weeks of age and there by it declined in older birds. Lillehoj and Trout (1996) stated that the lymphoid tissue was decreased by morphological involution and there was meager infiltration at 52 and 58 weeks of age in chicken. These cells may be wondering cells but might exists as immuno receptor cells as first line of defense, because in birds the immune system is more complex and composed of several cells and other factors that must works together to produce protective immune response (Yegani and Korver, 2008).

### 4. Caecum

In the caecum the diffuse lymphatic tissues as well as lymphatic nodules were observed. The caeco-colic junction showed the aggregation of lymphoid follicles in all the age groups which were predominant in Gr. II. These were referred as the caecal tonsil, which corresponds to this Peyer's patches in mammalian intestine. The solitary lymphatic nodules were observed on the mesenteric area of the intestine but few were also observed on the antimesenteric

portion. The follicles formed the dome and projected in the lumen. The epithelium covering the dome was simple columnar but was different from that of the villus epithelium and devoid of the goblet cells. The mucobacterial layer was found on the epithelial surface. In the epithelium of the lymphatic follicle few lighter cytoplasmic cells with large nucleus were also found between the columnar cells. These cells were designated as M cells. The diffuse lymphatic tissue of the caecum showed the lymphocytes, plasma cells, macrophages, and some eosinophils and erythrocytes. The aggregated lymphatic nodules in the caecum were of two types, encapsulated nodules and non-encapsulated nodules (Fig 5). The encapsulated nodules were covered by elastic and reticular fibers. The internodular connective tissue consisted of collagen fibers and some elastic fibers. The crypts of Lieberkuhn were observed between the populations of lymphatic nodules but distinct fossulae were not traceable. The different nodular units were distinct and separable in Gr. I birds, but in Gr. II and Gr., III the nodular units were inseparable in the caecal tonsil, although some were well demarcated. The germinal centers in the nodules of Gr. I were not well developed, but in Group II, Group III, (Fig 6) the lighter colored germinal centers were traceable. The observations in the present study are in accordance with the Pramod Kumar and Thandav Murthy (2007), Befus et. al. (1986) and Olaha and Glick (1979) in chicken, Kalitha et.al. (2010) in Kadaknath fowl and Ushakumary et.al. (2002) in Japanese quail. These results also corresponds to the mammalian Peyer's patches observed by Shukla and Singh (1996) in dogs, Lalitha (1991) in buffalo, Hanger and Heath in koala and Hemsley et.al. (1996) in possums. The well developed and highest occurrence of the lymphatic nodules in caecum is supported by almost all the authors referred above. The aggregation of nodules was observed in the caeco-colic junction in the present study but Ushakumary et.al. (2002) noticed the nodules in the proximal part of the caecum of the Japanese quail. Structurally the caecal tonsils, corresponds to the nodular units found in the mammals as palatine and lingual tonsils and hence the fact of the presence of caecal nodules in the chicken suggests that the luminal antigens are attacked in the caeca. The present study put on record the micrometrical observation on the lymphatic nodules of the caecal tonsils. The shape of the follicle was varied but mostly oval and rounded follicles were noted. Pramod Kumar and Thandav Murthy (2007) also recorded varying shapes of nodules but they stated that most of them were oval in shapes. There was significant difference in the size of lymphatic nodules in the different age groups of the present study, but Shukla and Singh (1996) stated that the average short and long diameter of solitary lymphatic nodules did not exhibit any regression even in adults. The goblet cells were absent. These findings

corroborates with that of the Burns and Maxell (1986). They also found some goblet cells, plasma cells, granulocytes, and globule leucocytes and mast cells in the epithelium. Kitagava et. al. (1998) also noted the M cells in the follicle associated epithelium, which were situated above the nuclear level of ordinary columnar epithelium cells. The exact role of M cell is not known but Hemsley et.al. (1996) stated that M cell are known to be important for sampling antigens from the intestinal lumen and transporting them to the underlying lymphoid tissues, where they can induce an immune response. They also suggested that there must be some association between M cells and intraepithelial lymphocyte of the follicles.

#### 5. Colon

The histomorphological observation, the lamina propria of colon showed extensive network of reticular fiber (Fig. 7). The diffuse lymphatic tissues were occurred in all the three groups of the present study, but major infiltration occurred in Gr. II and Gr. III. As compared to the other parts of the intestine there was less infiltration of lymphatic tissues in colon. There were numerous goblet cells. The IEL were not recorded. The solitary lymph nodules were observed but there was no aggregation as was seen in caecum, although in some part they were adjacent to each other. Their size was also smaller as compared to the ceacum. These observations are in accordance with Usha kumary et.al. (2002) in Japanese quail. Yegani and Korver (2008) also agreed that the lymphatic tissues distributed throughout the intestinal tract and represents the area of immune system but its distribution is not uniform across the different segments of the intestine.

There were no significant differences in the nuclear diameter of lymphocytes in different groups and also in the different parts of the intestine. It indicates that the lymphocytic proliferation, generation and their migration is continuous process in order to provide the immunity to the gastro intestinal mucosal surface.

#### 4. References

- [1] Bancroft, J.D.; and Stevens, A. (1982). In, "Theory and practice of Histological Techniques, 2nd Edition, Churchill Livingstone, Edinburgh.
- [2] Befus, A.D.; N.Johnston.; G.A. Leslie and J. Bienenstock (1986). Gut-associated lymphoid tissue in chicken. I. Morphology, ontogeny, and some functional characteristics of Peyer's patches. *J. Immunol* 125:2626-263.
- [3] Burns, R.B. and Maxwell, M.H. (1986). Ultra structure of Peyer's patches in the fowl and turkey, *J. Anat.* 147: .235-243.

- [4] Hanger, J.J. and Heath, T.J. (1994). The arrangement of gut - associated lymphoid tissues and lymph pathways in the koala (*Phascolarctos cinereus*). *J. Anat.* 185: 129-134.
- [5] Hemsley, S.W; Canfield P.J. and Husband A.J. (1996 a). The distribution of organized lymphoid tissue in the alimentary tracts of Koalas (*Phascolarctos cinereus*) and possums (*Trichosurus vulpecula* and *Pseudocheirus peregrinus*), *J. Anat.* 188: 269-278.
- [6] Hemsley, S.W; Canfield P.J. and Husband A.J. (1996 b). Histological and immunohistological investigation of alimentary tract lymphoid tissue in Koala (*Phascolarctos cinereus*) and brushtail possum (*Trichosurus vulpecula*) and ringtail possum (*Pseudocheirus peregrinus*). *J. Anat.*, 188:279-288.
- [7] Kalita, P.C.; Singh, G.K.; Dhote, B.S. (2010). Ultrastructure of gut associated lymphoid tissues in Kadaknath fowl. *I.J. Anim. Sci.* 80(4): 336-337.
- [8] Kitagawa, H. Hiratsuka Y., Imagawa, T, and Uehara, M.(1998). Distribution of lymphoid tissue in the caecal mucosa of chicken. *J. Anat.* 192: 293-298.
- [9] Lalitha P.S. (1991). Gut associated lymphoid tissue in Indian Buffalo, *Indian Vet J.* 68: 1057 – 1059.
- [10] Lalitha, P.S. (1994). Characteristic of Peyer's patches of new borne and older buffalo calves *IJVA* 6 (1): 101–106.
- [11] Lillehoj, H.S. and Trout, J.M. (1996). Avian Gut Associated Lymphoid Tissues and Intestinal Immune Responses to *Eimeria* Parasites. *Clinical Microbiology Reviews*: 349-360.
- [12] Olah, I and B. Glick (1979). Structure of the germinal centres in the chicken caecal tonsil. Light and Electron microscopic and auto radiographic studies. *Poult. Sci.* 58: 195 – 210.
- [13] Pramod Kumar D. and Thandava Murthy C. (1996). Micro anatomical studies on the caecal tonsil of white leghorn birds. *IJVA* 8(1/2): 12-15.
- [14] Pramod Kumar D. and Thandava Murthy C. (2007). Neonatal development of the caecal tonsil in white Leg Horn (WLH) birds. *IJVA* 19 (2): 18—21.
- [15] Rao, G.V. and Thomas, P.C. (1984). The breed characterization of Kadaknath breed of indigenous (Desi) chicken, *Avian Research*, 68:55-57
- [16] Samuelson, Don A. (2007). In “Textbook of Veterinary Histology” First edition, Saunders, Elsevier, Philadelphia, USA: 268.
- [17] Saxena, H.C. (2009). Indian Poultry Industry Exp. *World Poultry* 25 (9): 6-9
- [18] Shukla, S. and Singh, G.K. (1998). Anatomical Studies on Gut - associated Lymphoid tissue in Neonatal Pups *IJVA* 10 (1/2): 48 – 52.

[19] Singh, B; G.K. Singh and Rajesh Kumar (1994). Gross morphology of gut- associated lymphoid tissue (GALT) in young goats. IJVA 13: 95-96

[20] Sing, U.B. and S. Sulochana (1996). In Handbook of Histological and Histochemical Technique, 1st edition, premier publishing House, Hyderabad.

[21] Usha Kumary, S.; Geetha Ramesh and C. Vijayraghavan (2002). lymphoid aggregation in the caecum and the colon of Japanese quail. IJVA 14 (1/2): 16– 21.

[22] Yegani, M. and Korver, D.R. (2008). Factors Affecting Intestinal Health in Poultry. Poultry Science 87: 2052-2063

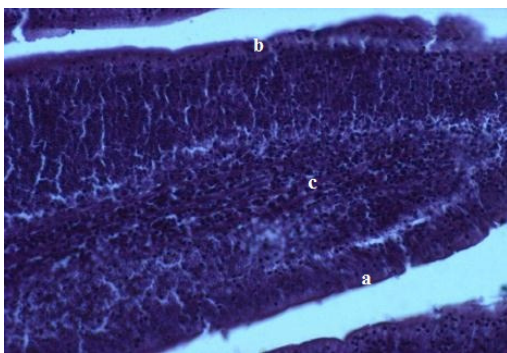


Fig 1: Photomicrograph of Duodenum (Gr.I) showing a) Epithelium b) Intraepithelial lymphocytes c) Lamina propria (HE 200 X)

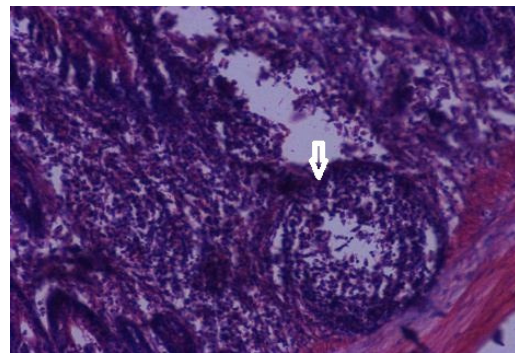


Fig 2: Photomicrograph of Duodenum (Gr.I) showing solitary lymphatic nodule (arrow) (HE 200 X)

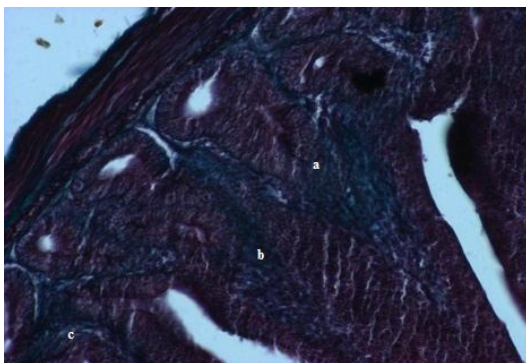


Fig 3: Photomicrograph of Jejunum (Gr. I) showing a) Collagen fibers b) Smooth muscle fibers c) Epithelium (Masson's trichome 200 X)

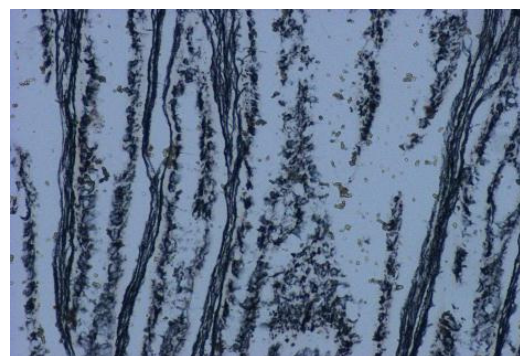


Fig 4: Photomicrograph of Ileum (Gr. III) showing reticular fibers in the villi. (Gomori's reticulin 200 X)

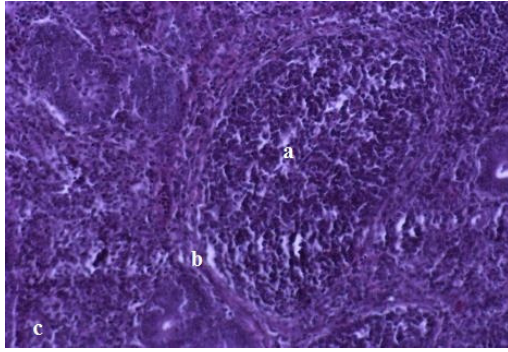


Fig 5: Photomicrograph of Caecum (Gr. I) showing a) Lymphatic nodule b) Capsule (200 X)

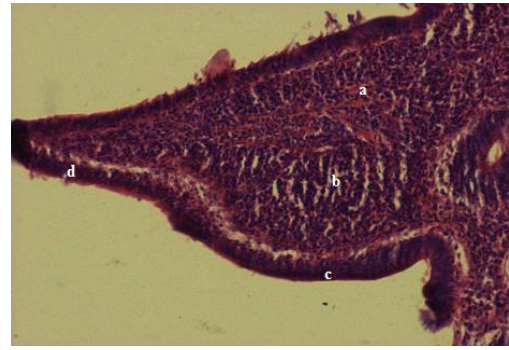


Fig 6: Photomicrograph of Caecum (Gr. III) showing a) Lymphatic nodule b) Diffuse lymphatic tissue c) Non villus epithelium d) Villus epithelium (HE 200)

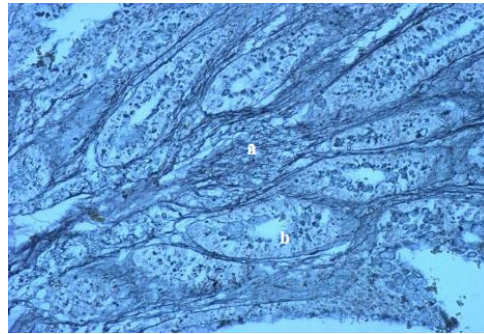


Fig 7: Photomicrograph of Colon (Gr. I) showing a) reticular fibers b) intestinal gland (Gomori's Retuculin 200 X)