

INCIDENCE AND TREATMENT OF ASPERGILLOSIS IN EMUS

CH. Sudha Rani Chowdary^{1*}, K. Poorani² and J. Jaya Lakshmi³

¹Department of TVCC, ³Department of Veterinary Parasitology

NTR college of Veterinary Science, Gannavaram, Andhra Pradesh

²SRF, College of poultry production and management, TANUVAS, Hosur, Tamil Nadu

E-mail: drsudha84@gmail.com (*Corresponding Author)

Abstract: The proportionate incidence of aspergillosis in Krishna district, Andhra Pradesh was found to be 13.17% during the period from January, 2010 to November, 2012. Clinical signs in aspergillosis affected birds were unthriftiness, ataxia, emaciation, respiratory distress, open mouth breathing, followed by sudden death. Gross lesions recorded were small, round, firm grayish white nodules in the lungs, air sacs, heart, liver and kidneys. Histopathologically the lesions were characterized by multifocal caseating granulomas in the lungs. The present study also aimed to report the therapeutic measures for aspergillosis using copper sulphate and ketoconazole to minimize economic losses.

Keywords: Aspergillosis, nodules, granulomas, copper sulphate, ketoconazole.

Introduction

There has been a quantum leap in the number of emu farms in Andhra Pradesh particularly in Krishna District in recent years, which were reared commercially for their meat, oil and skin [1].

Aspergillosis, the most common opportunistic mycotic infection of respiratory tract in birds would cause high morbidity and mortality. Acute cases were seen following inhalation of a high dose of spores due to heavy environmental contamination. *Aspergillus fumigatus* accounted for 95% of the cases and *A. flavus* was the second most common organism associated with avian infection [2]. Treatment of aspergillosis is complicated and relied on the use of antifungal medication. However, treatment is ineffective in poultry, which when tried it involved the use of one or more systemic antifungal agents. It was not usually done because it was expensive, prolonged, frequently associated with relapses and prognosis often guarded. Also the organism was usually walled off by the hosts' inflammatory immune response making systemic drugs inaccessible through blood stream [3].

Though many authors [2,4,5] have reported the occurrence of aspergillosis in emus, reports on the incidence of aspergillosis infection in emus in Andhra Pradesh (AP) was inadequate and its treatment has not been discussed.

Hence, a study has been undertaken to study the incidence of aspergillosis in Emus in AP and to compare the efficacy of Ketaconazole and copper sulphate in treating the disease.

Materials and Methods:

(I) Calculation of incidence of aspergillosis:

The current study was undertaken at Animal Disease Diagnostic Laboratory at Vijayawada, where Emu carcasses were regularly brought for necropsy from various Emu farms of Krishna District during the period from January, 2010 to November, 2012. Clinical history was recorded; detailed post mortem examination was conducted and gross lesions were documented.

Tissue samples (lungs, airsacs, liver and kidney) were collected for isolation of fungi and were fixed in 10% neutral buffered formalin for histopathological examination. The proportionate incidence of aspergillosis in Emus based on the post mortem reports from January, 2010 to November, 2012 was calculated using the formula,

Proportionate incidence of aspergillosis (%)

$$= \frac{\text{Total no. of cases of aspergillosis diagnosed on necropsy}}{\text{Total no. necropsies conducted}} \times 100$$

(II) Calculation of drug efficiency:

During the study (January, 2010 to November, 2012) three emu farms (I, II and III), which were aspergillosis positive were selected. With a sample size of 10 birds in each farm, the emu birds suffering from aspergillosis were subjected for drug efficacy studies.

In farm I, 0.25% copper sulphate in drinking water was administered orally to the ailing birds for 7 days. In farm II, 50 mg Ketaconazole dissolved in 5ml of water was administered orally to each ailing bird for 7 days. In farm III, both 0.25% copper sulphate in drinking water along with 50 mg ketaconazole per bird were administered for 7 days.

Drug efficacy was calculated using the formula,

$$\text{Drug efficacy (\%)} = \frac{\text{Total no. Of birds recovered after treatment}}{\text{Total no. of birds affected}} \times 100$$

Results:

During the study period, a total number of 258 emu birds were presented for necropsy. Among those, 34 birds in the age group of 5-9 weeks belonging to 9 Emu farms were found positive for aspergillosis (*Aspergillus fumigatus*) based on microbial culture. The proportionate incidence of aspergillosis was found to be 13.17%.

Clinical signs reported in the affected birds in these 9 farms were dullness, unthriftiness, ataxia, emaciation, respiratory distress and open mouth breathing. Upon gross examination of the carcasses at necropsy, all the carcasses revealed grayish white firm nodules of 0.1 to 0.4 cm diameter in the lungs (Fig. 1) and thoracic air sacs. In three cases, these nodules were found on the heart, air sacs, liver and kidneys.

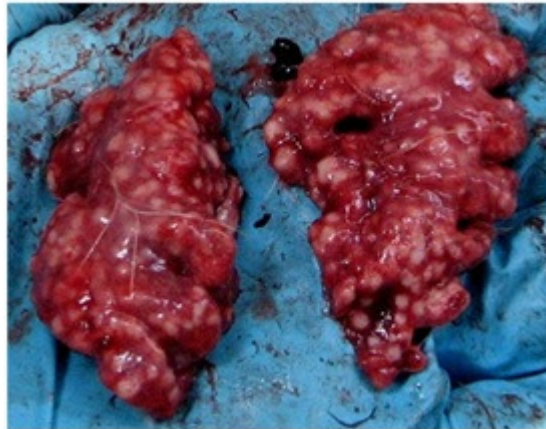

Fig.1 Grayish white nodules in the lung parenchyma.

Histopathological examination of lung nodules showed multiple caseating granulomas characterized by a central caseated mass with degenerated heterophils surrounded by lymphocytes, macrophages, epithelioid cells and multi nucleated foreign body giant cells along with fibrous tissue encapsulation. Intense vascular changes varying from hemorrhages to thrombosis were evident. Septate and branching fungal hyphae were demonstrated by PAS staining in the caseated lung nodules (Fig. 2).

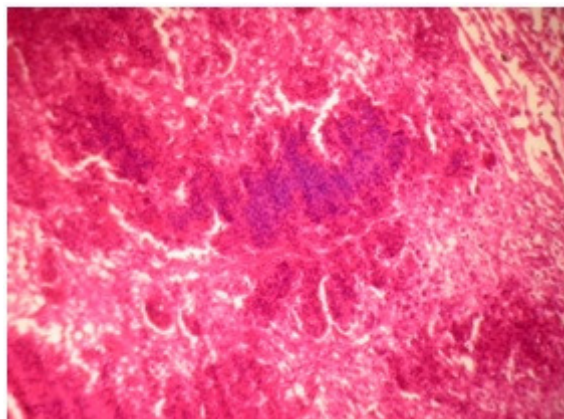


Fig.2. Histopathology of a lung nodule showing caseating granuloma. HE, 100x.

In Group- I Emu farm, 0.25% copper sulphate was administered orally for 7 days. 5 birds recovered completely without showing any clinical signs and rest of the birds died within the period of seven days. The drug efficacy was found to be 50%.

In Group-II Emu farm, Ketaconazole was administered at the rate of 50 mg in 5ml drinking water per bird orally for seven days. Seven birds recovered after seven days of treatment. 2 birds showed clinical signs of mild respiratory distress and 1 bird died on the second day of the treatment. The drug efficacy was found to be 70%.

In Group-III Emu farm, Both Ketaconazole at the rate of 50 mg per bird in 5ml drinking water and 0.25% copper sulphate were administered orally for seven days. 9 birds recovered at the end of the treatment. 1 bird was found to be dull and off feed. The drug efficacy in this group was found to be 90%.

Discussion:

In the present study, the proportionate incidence of aspergillosis was found to be 13.17%, belonging to the age group of 5-7-weeks-old in Krishna district of Andhra Pradesh. The incidence of aspergillosis has been reported by many authors [2,4,5], however incidence in Andhra Pradesh was rarely reported.

Karunakaran *et al.* (2010) [5] reported that young birds in enclosed facility were most susceptible individuals for infection. *Aspergillus* spp. exposure can occur through egg contamination but, under current conditions in the industry, poorly managed intensive chick facilities seem to be the most likely place for an outbreak to occur. Aspergillosis would proliferate in environments with a high humidity and relatively warm temperatures. Warm, moist areas such as in litter, around waterers, spoiled or damp feed, rotting vegetation etc. provide suitable environment for the proliferation of the fungus. Young chicks are more susceptible to infection. Under current scenario poorly managed chick facilities was found to be more likely to transmit the disease apart from egg contamination [6]. *Aspergillus* genus is an opportunistic pathogen and the disease aspergillosis has a poor prognosis when the tissue infection is extensive. Therefore, every attempt should be made to reduce predisposing immunosuppressive factors such as stress and malnutrition. Warm and humid environments tend to increase incidence of the disease. Infection sets in immune-deficient birds, where it is in developing stage, or among the birds that have been stressed through other diseases or problems such as overcrowding, insufficient food and water [7]. To avoid inhalation of large number of spores, birds should be housed in ventilated area with sufficient space allotted and also to prevent access to mouldy feed [2].

Clinical signs in the affected birds in these 9 farms were dullness, unthriftiness, ataxia, emaciation, respiratory distress and open mouth breathing. Similar findings were reported by Karunakaran et al. (2010) [5] and Eswaran et al (2011) [2]. Clinical signs such as dyspnoea and open mouth breathing are may be due to progressive air way obstruction [7].

Gross and histopathological findings were in accordance with Karunakaran *et al* (2010) [5] and Eswaran *et al.* (2011) [2], where they isolated *Aspergillus fumigatus* from firm nodules in SDA agar. However, presence of nodules on airsacs, heart, liver and kidney might have been due to rapid dissemination of spores through hematogenous route to other tissue.

In this study, drug efficacy in combination therapy of copper sulphate and Ketaconazole was found highly effective followed by treatment with Ketaconazole and copper sulphate. Eswaran *et al.* (2011) [2] reported that administration of copper sulphate orally for 3 days could alleviate the clinical signs.

In the present study, farmers were advised good managemental practices, which would reduce juvenile stress and potential exposure to the fungi.

References

- [1] Chowdary CHSR, Kumar CSVS, Lakshmi JJ and Devi MA. (2015). Infectious etiologicals causing mortality in emu birds. *Intas Polivet.* **16**: 485-486.
- [2] Eswaran MA, Sukumar K, Malmarugan S, Poomathi K and Rajeswar, JJ. (2011). Pulmonary aspergillosis in Emus (*Dromaius novaehollandiae*). Tamilnadu J. Veterinary & Animal Sciences **7 (5)**: 254-255.
- [3] Musa IW, Aliyu G and Ismail A. (2014). Aspergillosis in broilers: Reports of 3 cases from a commercial and 2 broiler breeder farms in Zaria, Nigeria. *Int. J. Curr. Microbiol. App. Sci.* **3**: 932-938.
- [4] Chakravarthy I. (1976). A case history of mycotic infection (aspergillosis) in an emu (*Dromaius novaehollandiae*) in Delhi Zoo. *Indian Veterinary Journal.* **53**: 881-882.
- [5] Karunakaran S, Nair KG, Nair ND and Mini M. (2010). Systemic aspergillosis in emu chicks in an organized farm in Kerala. *Veterinary World.* **3 (10)**: 453-455.
- [6] Tully TN and Shane SM. (1996). Husbandry practices as related to infectious and parasitic diseases of farmed ratites. *Rev. Sci.tech.off.int.Epiz..* **15(1)**: 73-89.
- [7] Jordan FTW. (1990). *Poultry Diseases*. IIIrd edn. English Language Book Society. London, pp.216-217.