

*Clinical Article*

**GANGRENOUS MASTITIS IN A EWE**

**Amaravathi M<sup>\*1</sup>, Bharath Kumar Reddy C<sup>2</sup> and Jyosthna Devi S<sup>3</sup>**

Veterinary Dispensary, Kadapa – 516 259, Andhra Pradesh

<sup>1</sup>Ph.D Scholar, Department of Veterinary Pathology, C.V.Sc, Tirupati

<sup>2</sup>Ph.D Scholar, Department of Veterinary Medicine, C.V.Sc, Tirupati

<sup>3</sup>Veterinary Assistant Surgeon, Chakrayapet, Kadapa

E-mail: ammu.nihal@gmail.com (\*Corresponding Author)

**Abstract:** A case of gangrenous mastitis was surgically treated in an ewe aging 3 years and weighing 24 kg at Veterinary Dispensary, Chakrayapeta. Diagnosis was made based on the physical changes of udder and milk sample. Parenteral administration of Gentamycin and concurrent intra-mammary infusion of Penicillin along with supportive treatments for one week could not save the quarter, rather the condition deteriorated. Mastectomy was done and the ewe recovered without any complication after 10 days of post-treatment and management.

**Keywords:** Ewe, Gangrenous Mastitis, Mastectomy.

**Introduction**

Mastitis is one of the more common health problems affecting sheep and it has a major impact on both economy and animal welfare. It frequently causes partial or complete damage to the clinically affected glands leading to reduced milk yield and retarded growth of the lambs (Fthenakis and Jones, 1990). Gangrenous mastitis is one of the most difficult forms of mastitis to be treated (Bloway, 1993) and in very severe cases, the gangrene may lead to toxemia and loss of animal life (Ribeiro et al., 2007). In very severe cases, gangrene may develop in the mammary gland and the ewe may die. A wide range of microorganisms cause mastitis in sheep but, most cases are reported to be due to *Staphylococci* infection (Bergonier and Berthelot, 2003). This clinical case report describes the surgical management of gangrenous mastitis in an ewe.

**Case History and observations**

A 3 years old ewe weighing 24 kg was presented to the Veterinary Dispensary, Chakrayapeta, Kadapa district of Andhra Pradesh with a history of anorexia and lameness. Clinical examination revealed slightly elevated body temperature (104<sup>0</sup> F) and mildly congested mucus membranes. Heart rate and respiration rate were within the normal range. Examination of the udder revealed marked swelling and was cold upon touch. The affected teat revealed blood tinged milk (**Fig. 1**) and the skin of the affected quarter was indurate with reddish-black discoloration (**Fig. 2**). Whole blood was collected for haematological examination.

### **Treatment and Discussion**

Initially, the ewe was treated with 3 ml Gentamycin intramuscularly along with intramammary infusion of Penicillin 4 ml and Inj. Rintose (Dextrose anhydrous, Sodium chloride, potassium chloride and Calcium chloride) was given @ 250 ml intravenously for one week. Haematology (Total Leukocyte count, haemoglobin and Differential leukocyte count) revealed no abnormalities. As a supportive treatment, injection Vitamin B complex (Tribivet) @ 3 ml/day was given intramuscularly and Meloxicam @ 0.5 mg/kg body weight for 7 days. There was no improvement inspite of therapy and hence, we decided to proceed for mastectomy to save the life of the ewe.

### **Surgical Procedure**

The ewe was controlled by left lateral recumbency with epidural anesthesia using 2% solution of Lidocaine HCl dosed at 3 ml. Ring block was also done locally with 20 ml of 2% Lidocaine. Antiseptic washing was done properly. About 7-8 cm skin incision at the border of the affected udder part was performed. Then affected quarter was removed and the area was sprayed by 0.5% Metronidazole saline to protect from secondary bacterial infection. Finally, after mastectomy, skin was closed with proper apposition and the skin tension was normal. Gangrenous tissue appeared as black colour and sharply demarcated from unaffected area (**Fig. 2**). Further, confirmation was made that there was no more gangrenous or dead tissue inside the suture. Proper post operative care with antibiotics and anti-inflammatory drugs was taken for 10 days.

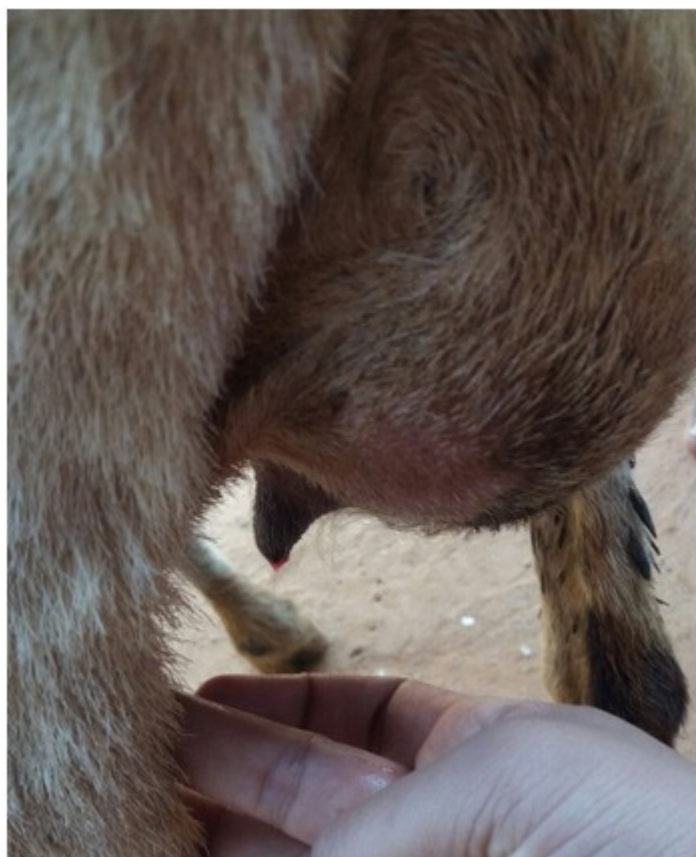
Gangrenous mastitis is a per-acute form of mastitis, characterized by necrosis of the udder tissue, caused by alpha-toxins (Smith and Sherman, 2009). Physical examination of the udder is characterized by discolored (blue- blackish or blue-greenish) and cold udder (Ribeiro et al., 2007); similar findings were also observed in the present study. In gangrenous mastitis, surgical removal of the dead and dying tissue is an immediate management option. Surgical treatment of the gangrenous mastitis in this case was in accordance with several other case reports (Ribeiro et al., 2007 and Pal et al., 2011).

### **Conclusion**

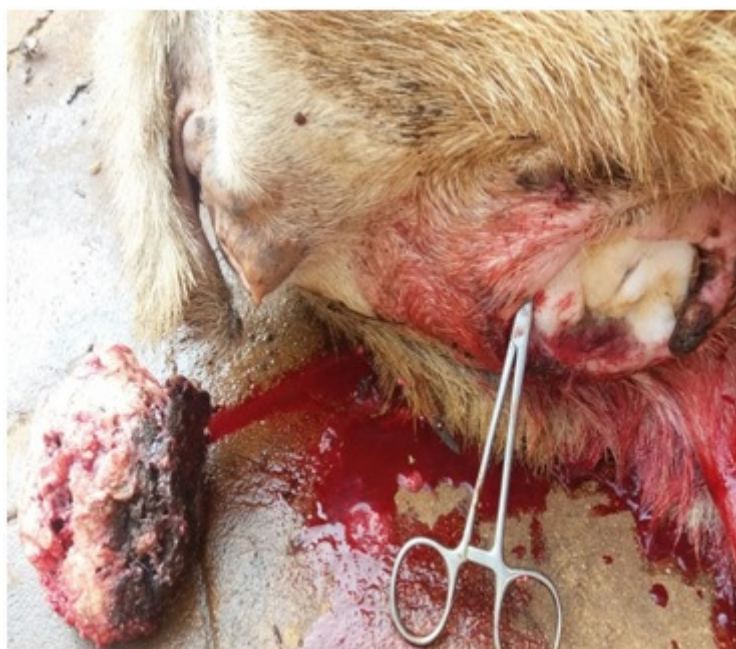It could be concluded that the therapeutic management alone is not effective for treatment of gangrenous mastitis unless, early surgical removal of the affected quarter is undertaken which is the only standard treatment for gangrenous mastitis in ewes.

## References

- [1] Bergonier D and Berthelot X 2003 New advances in epizootiology and control of ewe mastitis. *Livestock Production Science*, 79: 1-16.
- [2] Bloway R W 1993. The treatment of different cases of mastitis. In: Proc. British Mastitis Conference, pp 63-69.
- [3] Canle C S, Perry C, Fubini and Susan L 2004 Radical mastectomy in 20 ruminants. *Veterinary Surgery*, 33: 263-266.
- [4] Fthenakis G.C and Jones J.E.T 1990 The effect of experimentally induced subclinical mastitis on milk yield of ewes and on the growth of lambs. *British Veterinary Journal*, 146: 43-49.
- [5] Pal B, Wadhwa D.R, Mandial R.K and Sharma M 2011 Acute and per-acute gangrenous mastitis in goats and its management. *Intas Polivet*, 12: 63-64.
- [6] Radostits O.M, Gay C.C, Blood D C and Hinchcliff K.W 2000 *Veterinary Medicine. A textbook of disease of cattle, sheep, pig, goat and horses*. Bailliere, Tindall, London.
- [7] Ribeiro M.G, Lara G.H.B, Bicudo S.D, Souza A.V.G, Salerno T, Siqueira A.K and Geraldo J.S (2007). An unusual gangrenous goat mastitis caused by *Staphylococcus aureus*, *Clostridium perfringens* and *Escherichia coli* co-infection. *Brazilian Journal of Veterinary and Animal Science*, 59: 810-812.

**LIST OF FIGURES**

**Figure 1:** Ewe showing enlarged udder with reddish-black discoloration and blood tinged milk from affected teat



**Figure 2:** Gangrenous tissue showing black discoloration and sharply demarcated from unaffected area